

GUIDELINE ON DIAGNOSIS AND MANAGEMENT OF ENDOMETRIOSIS 2026



**Ministry of Health,
Family and Welfare**
Republic of Maldives

RELEASE RECORD

Version Number	Version Date	Description of change
1	14.06.2026	Initial release

DOCUMENT NUMBER: MOH-QA/G/26/245-0

Principle Authors:	<p>Dr. Mohamed Aseel Jaleel Senior Consultant, Obstetrics and Gynaecology President, Society of Obstetricians and Gynaecologists of Maldives</p> <p>Dr. Hawwa Hana Senior Consultant of Obstetrics and Gynaecology, Gynaecological Oncology Focal point for Gynaecological Oncology (SOGM SAFOG Subcommittee), Society of Obstetricians and Gynaecologists of Maldives</p> <p>Dr. Shanaz Dole Senior Consultant of Obstetrics and Gynaecology, Minimally Invasive Gynaecological Surgery Organising Secretary, Society of Obstetricians and Gynaecologists of Maldives</p>
Contributors:	<p>Dr. Shirmeen Mohamed Senior Consultant of Obstetrics and Gynaecology Executive Member, Society of Obstetricians and Gynaecologists of Maldives</p> <p>Dr. Hussain Juman Jaleel Consultant, Obstetrics and Gynaecology Secretary, Society of Obstetricians and Gynaecologists of Maldives</p> <p>Dr. Fathimath Shamaa Shareef Specialist, Obstetrics and Gynaecology Focal point for Education Subcommittee (SOGM SAFOG Subcommittee), Society of Obstetricians and Gynaecologists of Maldives</p>
Expert Panel:	<p>Prof. Dr. Parol Kotdawala Past Chairperson Indian College of Obstetrics and Gynaecology Advisor and Ex-Chairperson: Education Committee (SAFOG) Hon. Endoscopy Surgeon in Obstetrics and Gynaecology, LG Hospital and Narendra Modi Medical College, Ahmedabad, India</p>

Peer Reviewers:	<p>Dr. Jabeen Ali Shareef Consultant in Obstetrics and Gynaecology, SOGM</p> <p>Dr. Thasneem Farooq Senior Consultant in Obstetrics and Gynaecology, IGMH</p> <p>Dr. Aminath Shaheedha Senior Consultant in Obstetrics and Gynaecology, TTH</p> <p>Dr. Aishath Shibana Ahmed Senior Consultant in Obstetrics and Gynaecology, IGMH</p> <p>Dr. Hawwa Inaya Abdul Raheem Senior Consultant in Obstetrics and Gynaecology, HMM</p> <p>Dr. Munuswamy Narayan Sampath Senior Consultant in Obstetrics and Gynaecology, TTH</p> <p>Dr. Leena Saleem Consultant in Obstetrics and Gynaecology, ADK</p> <p>Dr. Aminath Nazeer Senior Consultant in Radiology, IGMH</p> <p>Dr. Aminath Arifa Senior Consultant in Radiology, IGMH</p> <p>Dr. Ibrahim Rasheed Senior Consultant in Radiology, Care Trust Hospital</p> <p>Dr. Basma Ibrahim Senior Consultant in Radiology, IGMH</p> <p>Dr. Fathimath Mufliha Senior Consultant in Radiology, IGMH</p>
Acknowledgements:	<p>Mariyam Neesha Quality Assurance and Regulations Department Ministry of Health, Family and Welfare, Maldives</p>
Endorsed by:	<p>Uza. Thasleema Usman Commissioner of Quality Assurance</p>
Developed by:	<p>Society of Obstetricians and Gynaecologists of Maldives (SOGM) in collaboration with Ministry of Health, Family and Welfare</p>
Published by:	<p>Ministry of Health, Family and Welfare</p>

Contents

1.0 Background 5

2.0 Scope of the guideline 6

3.0 Classification of Endometriosis..... 7

4.0 Diagnosis of Endometriosis 8

5.0 Treatment of Endometriosis-Associated Pain..... 15

6.0 Treatment of Endometriosis-Associated Infertility..... 31

7.0 Recurrence and Secondary Prevention of Endometriosis 34

8.0 Endometriosis in Adolescents 39

9.0 Management of Postmenopausal Women with Endometriosis 47

11.0 Management of Asymptomatic Endometriosis..... 54

12.0 Primary Prevention of Endometriosis 55

13.0 Endometriosis and Cancer Risk 57

14.0 Referral Pathway..... 59

15.0 Appendix 60

16.0 References..... 85

1.0 Background

Endometriosis is a chronic, estrogen-dependent inflammatory condition characterized by the presence of endometrial-like tissue outside the uterine cavity.

It is a common gynecological disorder affecting approximately 10% of women of reproductive age worldwide, with disease prevalence increasing to 30% in infertile women and 40-60% in women with dysmenorrhea. It is associated with significant morbidity, including chronic pelvic pain, dysmenorrhea, dyspareunia, and subfertility. Despite its high prevalence and substantial impact on quality of life, there is currently no definitive cure, and the condition remains frequently under-recognized.

A major challenge in endometriosis care is the delay in diagnosis, which is estimated to average 7–11 years from symptom onset. This diagnostic delay often results in prolonged physical suffering, psychological distress, and reduced social and occupational functioning. Historically, normalization of menstrual pain and limited awareness among both patients and healthcare providers have contributed to these delays.

In recent years, increased public and professional awareness, supported by patient advocacy and social media engagement, has brought greater attention to endometriosis as an important public health issue. This shift has stimulated stronger collaboration among policy makers, healthcare professionals, researchers, and patient communities to improve recognition, diagnosis, and management of the disease.

Advances in imaging and diagnostic modalities have further contributed to earlier detection and improved clinical evaluation. Although definitive cure remains elusive, early diagnosis and timely intervention are critical in improving symptom control, reducing disease progression, and empowering women through validation of their symptoms and informed decision-making.

In the Maldives, recognition and structured management of endometriosis are still at an early stage of development. Nevertheless, the burden of disease on individuals and society is considerable and comparable to that of other major chronic illnesses.

Encouragingly, there is growing acknowledgment among policy makers and healthcare leaders of the importance of integrating endometriosis care into broader women's health strategies. These guidelines aim to support improved awareness, standardized care, and evidence-based management tailored to the local context.

2.0 Scope of the guideline

This guideline is intended for healthcare professionals, including primary care providers, Medical Officers, General practitioners and Specialist Gynaecologists and other Specialists involved in the diagnosis and management of Endometriosis and associated conditions.

3.0 Classification of Endometriosis

3.1 Morphological Classification

Classify endometriosis into the following categories:

- Superficial peritoneal disease
- Ovarian endometriosis (endometrioma)
- Deep infiltrating endometriosis (DIE) or deep endometriosis (DE)
 - DIE is conventionally defined as lesions invading >5 mm beneath the peritoneal surface.
 - Recently, lesions arising with fibrous or myogenic tissue from adenomyosis-like tissue (adenomyosis externa) have also been clinically addressed as deep endometriosis.

Consider involvement of pelvic organs, including:

- Bladder
- Bowel
- Pelvic side wall
- Retroperitoneal structures
- Extrapelvic endometriosis may occur, including involvement of thoracic or abdominal wall.

3.2 Surgical Staging

- Use the revised American Society of Reproductive Medicine (rASRM) staging system for surgical classification of endometriosis.
- Recognize that rASRM staging does not predict symptom severity, pain intensity, or prognosis.
- Do not use rASRM stage alone to guide symptom management or fertility counseling.
- Use the #Enzian Classification to complement the rASRM system for surgical staging of deep endometriosis when identified
- Use the Endometriosis Fertility Index (EFI) scoring system to estimate the likelihood of pregnancy after surgical staging of endometriosis.

Refer to Appendix for Staging Systems

4.0 Diagnosis of Endometriosis

4.1 Principles of Diagnosis

- Ensure early diagnosis and timely treatment in individuals with suspected or confirmed endometriosis.
- Recognize that diagnostic delay may significantly impair quality of life and contribute to disease progression.
- Do not delay evaluation in symptomatic individuals.

4.2 Risk Factors

Consider increased likelihood of endometriosis in individuals with the following risk factors:

- Early menarche (≤ 12 years)
- Short menstrual cycle length (≤ 26 days)
- Heavy menstrual bleeding affecting quality of life
- Lean body habitus
- Nulliparity
- First-degree relative with endometriosis
- Neonatal uterine bleeding

Ensure risk factors are considered within the clinical context and not used in isolation to confirm or exclude diagnosis.

4.3 Signs and Symptoms

- Recognize that signs and symptoms are variable and may not correlate with disease stage.
- Do not exclude severe disease based on mild symptoms or minimal disease based on severe symptoms.

Clinical Features

Consider endometriosis in women and adolescents (including those aged 17 years and under) presenting with one or more of the following cyclical or non-cyclical symptoms:

- Dysmenorrhea
- Deep dyspareunia
- Dysuria
- Dyschezia
- Painful rectal bleeding
- Tenesmus
- Constipation and diarrhea
- Haematuria
- Shoulder tip pain
- Catamenial pneumothorax
- Cyclical cough or haemoptysis
- Chest pain
- Cyclical scar swelling and pain
- Fatigue
- Infertility
- Consider extrapelvic endometriosis in individuals with cyclical thoracic or scar-related symptoms.

4.4 Symptom Documentation

- Use symptom tracking tools to help objectify pain patterns and empower individuals to describe symptom burden.
- Consider use of symptom diaries or questionnaires to complement clinical history-taking.
- Do not rely solely on symptom diaries, questionnaires, or mobile applications to establish diagnosis.
- Current evidence does not demonstrate reduction in diagnostic delay through their use alone.

4.5 Clinical Examination

- Perform abdominal, pelvic (internal), and rectal examination where clinically appropriate and acceptable to the individual.
- Ensure informed consent and sensitivity during examination.

4.5.1 Abdominal Examination

- Identify abdominal masses or localized tenderness.

4.5.2 Pelvic Examination

Assess for:

- Reduced uterine or adnexal mobility
- Uterine enlargement
- Uterine retroflexion
- Tender nodularity in the posterior vaginal fornix
- Visible vaginal endometriotic lesions
- Pelvic tenderness
- Consider adhesions when limited organ mobility is present.

Do not exclude endometriosis if clinical examination is normal.

4.5.3 Rectal Examination

- Perform rectal examination when rectouterine or posterior compartment disease is suspected.
- Rectovaginal pouch lesions may be palpable as tender nodularity or fibrotic induration.
- Adhesions in the rectovaginal pouch and around the adnexa are characteristic findings.

Do not exclude endometriosis if clinical examination is normal.

4.6 Biochemical Tests

- Recognize that CA125 levels may be elevated in endometriosis, and may rise acutely in cases of ruptured or hemorrhagic ovarian endometriomas.
- Do not use serum CA125 to diagnose endometriosis. There are no definitive biomarkers currently for diagnosis of endometriosis.
- Do not interpret CA125 in isolation; if used, interpret in conjunction with clinical and imaging findings.

4.7 Imaging

Use imaging (Ultrasound or MRI) in the diagnostic work-up for endometriosis, but clinicians need to be aware that a negative finding does not exclude endometriosis, particularly superficial peritoneal disease.

4.7.1 Ultrasound

- Offer transvaginal ultrasound scan (TVS) to all individuals with suspected endometriosis, even if pelvic or abdominal examination is normal.
- Use high-quality transvaginal ultrasound to identify:
 - Ovarian endometriomas
 - Deep infiltrating endometriosis (including bowel, bladder, or ureter involvement)
 - Alternative pelvic pathology
- Use a systematic and structured approach when performing ultrasound examinations for suspected endometriosis.

- Ensure all examination findings are comprehensively and accurately documented.
- Recognize that high-quality TVS is comparable to MRI for detection of endometriomas and deep endometriosis.
- If transvaginal ultrasound is declined or not suitable, offer transabdominal pelvic ultrasound as an alternative.
- Do not exclude endometriosis if abdominal or pelvic examination and ultrasound findings are normal.
- Perform ultrasound of kidneys, ureters and bladder in patients with suspected or diagnosed deep infiltrating endometriosis.
- Ensure referral to specialist care when clinical suspicion remains high, despite normal imaging.

4.7.2 MRI

- Consider MRI when:
 - Transvaginal ultrasound is inconclusive or not feasible.
 - Deep infiltrating endometriosis (DIE) is suspected.
 - Bowel, bladder, ureteric, or retroperitoneal involvement is suspected.
 - Preoperative mapping of disease extent is required.
- Interpret MRI studies systematically, with focused assessment for the presence, extent, and characteristics of endometriotic lesions.
- Ensure MRI is interpreted by clinicians with expertise in endometriosis imaging.

4.7.3 Imaging versus Diagnostic Laparoscopy

- A dedicated transvaginal ultrasound in experienced hands, and MRI, can replace surgery as the gold standard for the diagnosis of ovarian endometriotic cysts and deep pelvic endometriosis.
- Superficial peritoneal endometriosis cannot currently be reliably diagnosed or ruled out using existing imaging techniques.
- Laparoscopy remains superior for detection of superficial peritoneal endometriosis.

4.8 Empirical Treatment versus Diagnostic Laparoscopy

4.8.1 Empirical (Blinded) Medical Treatment

- Consider empirical hormonal treatment as first-line therapy in symptomatic individuals with suspected endometriosis, when:
 - Imaging results are negative, and
 - The individual is not actively attempting conception.
- Use combined oral contraceptives or progestogens as first-line empirical therapy.
- Consider a single injection of GnRH agonist as empirical treatment. In patients with endometriosis, significant reduction in pain is observed during subsequent menstrual cycle.
- Presume a diagnosis of endometriosis if symptoms improve with hormonal therapy, although it does not exclude the possibility of co-existing conditions.

4.8.2 Diagnostic Laparoscopy

- Consider diagnostic laparoscopy when:
 - Symptoms persist despite empirical medical therapy,
 - The individual declines hormonal treatment,
 - Imaging is negative but symptoms persist
 - Imaging suggests advanced or deep disease requiring surgical planning,
 - Fertility evaluation is indicated.
 - Diagnosis remains uncertain
- Ensure that individuals are counseled regarding the invasive nature of laparoscopy, surgical risks, and the potential need for concurrent therapeutic intervention.
- Do not delay appropriate symptom management while awaiting definitive surgical diagnosis.
- Ensure histological confirmation where feasible.

- Ensure individualized care based on symptom severity, fertility wishes, access to imaging and surgical expertise, and patient preference.

Both diagnostic laparoscopy and imaging combined with empirical treatment (hormonal contraceptives or progestogens) can be considered in women suspected of endometriosis.

There is no evidence of superiority of either approach and pros and cons should be discussed with the patient.

5.0 Treatment of Endometriosis-Associated Pain

5.1 General Principles

- Recognize that endometriosis is a chronic and, in many individuals, incurable condition.
- Ensure patients are counseled that available treatments aim to reduce pain and improve quality of life but may not provide permanent cure.
- Inform patients that symptom relief is often partial and may be temporary, and that recurrence of symptoms is common after discontinuation of therapy.

5.2 Structure of Management

- Adopt a structured and stepwise approach to the management of endometriosis associated pain, including:
 1. Empirical treatment
 2. Medical treatment
 3. Surgical treatment
 4. Preoperative and postoperative medical treatment (including secondary prevention after surgery)
 5. Non-medical management strategies
- Ensure individualized treatment planning, taking into account symptom severity, disease extent, fertility wishes, prior treatment response, and patient preference.
- Use shared decision-making when selecting treatment modalities

5.3 Analgesics

5.3.1 Non-steroidal anti-inflammatory drugs and acetaminophen

- Offer a short trial, 3 months, of simple analgesics (paracetamol or non-steroidal anti-inflammatory drug, NSAIDs) alone or in combination as first line management for endometriosis-associated pain.

- Use analgesics as part of multimodal care, including alongside hormonal treatment or surgery if needed.
- Recognize that many patients use over-the-counter analgesics before specialist review.
- Inform that analgesics do not affect disease progression.
- Consider NSAIDs for their analgesic and anti-inflammatory effects.
- Inform patients about possible gastrointestinal side effects of NSAIDs.
- Use the lowest effective dose for the shortest duration necessary.

5.3.2 Neuromodulators

- Consider neuromodulators in chronic or persistent pain, especially if central sensitization is suspected.
- Recognize that they act on central pain pathways, not inflammation.
- Use preferably under specialist guidance.
- Inform patients about possible dose-limiting side effects and that current evidence does not show clear superiority over placebo in chronic pelvic pain.
- Examples include:
 - Tricyclic antidepressants (e.g., amitriptyline, nortriptyline)
 - SSRIs/SNRIs (e.g., duloxetine)
 - Anticonvulsants (e.g., gabapentin, pregabalin)

5.3.3 Additional Considerations

- Consider early pain control to potentially reduce complications of chronic pain, including peripheral and central sensitization.
- Do not use analgesics as sole long-term therapy in moderate-to-severe disease without evaluation for disease-directed treatment.
- Ensure regular review of treatment effectiveness and tolerability.

5.4 Hormonal Treatments

➤ General Principles

- Recognize that endometriosis is a steroid-dependent condition.
- Use hormonal therapy to suppress ovarian activity or act on steroid receptors within lesions.

➤ Treatments include:

- Progestogens
- Combined hormonal contraceptives
- GnRH agonists
- GnRH antagonists
- Levonorgestrel intrauterine system (LNG-IUS)
- Aromatase inhibitors (e.g., letrozole)
- Anti-progestogens
- Danazol

➤ Effectiveness

- Recognize that all hormonal treatments reduce endometriosis-associated pain compared with placebo.
- Inform patients that individual response and tolerability vary and that no hormonal treatment is free of side effects.
- Inform patients that effectiveness is broadly similar across different hormonal options that selecting the most suitable therapy often requires trial and error.

➤ Clinical Considerations

- Offer hormonal treatment (combined hormonal contraceptives, progestogens) as a first-line option for pain reduction.
- Do not assume superiority of one hormonal treatment over another.
- Consider individual preferences, side effects, efficacy, costs, and availability.

- Discuss contraceptive effects, which may be beneficial or undesirable depending on fertility wishes.
- Inform patients that there is no evidence that hormonal treatments worsen disease progression.
- Provide detailed counselling on expected benefits and side-effect profiles before initiation.

5.4.1 Combined Hormonal Contraceptives (CHCs)

➤ **Efficacy**

- Offer combined oral contraceptives (COCPs) to reduce dysmenorrhea, dyspareunia and cyclical non-menstrual pelvic pain, noncyclical pelvic pain.
 - OCPs significantly reduce endometriosis-associated pain.
 - OCPs improve quality of life in most studies.
 - OCPs are effective, safe, cost-effective and often provide contraception.

➤ **Continuous vs Cyclic Use**

- Consider continuous OCP, rather than standard cyclic use, as an effective treatment for endometriosis associated dysmenorrhea.
 - Continuous use achieves amenorrhea.
 - Continuous use may reduce dysmenorrhea recurrence compared with cyclic use.
 - The difference between continuous and cyclic use for chronic pelvic pain and dyspareunia are non-significant.
 - Safety profiles appear similar between continuous and cyclic regimens.-

➤ **Routes of administration for CHC:**

- Oral contraceptive pill
- Vaginal ring
- Transdermal patch

- Recognize that limited comparative data are available between different administration routes.
- Do not recommend one route over another based on current evidence.
- Use patient preference, tolerability, availability and practical considerations to guide choice of administration.
- Use shared decision-making when prescribing CHCs.
- Consider contraceptive needs when selecting treatment.

5.4.2 Progestogens

➤ **Efficacy**

- Offer progestogens to reduce endometriosis-associated pain.
 - Progestogens are effective for dysmenorrhea, chronic pelvic pain and dyspareunia.
 - Levonorgestrel-releasing intrauterine system (LNG-IUS) and etonogestrel (ENG) implant are equally effective options.
 - LNG-IUS shows similar efficacy to GnRH agonists for pain reduction, with LNG-IUS offering clinical advantages and better side effect profile.
 - Long-term use of dienogest improves endometriosis associated pain.

➤ **Safety and Side-Effects**

- Inform patients about common side effects, including irregular bleeding, amenorrhea, weight gain, bloating, acne and mood changes.
 - Depot progestogens may cause more bleeding irregularities and injection site reactions, bloating, intermenstrual bleeding, weight gain, and amenorrhea compared with other treatments.
 - Oral progestogens are associated with amenorrhea and breakthrough bleeding.
- Monitor bone health in long-term depot medroxyprogesterone acetate (DMPA) use for more than 2 years, or earlier, where appropriate.
- Use shared decision-making when selecting progestogen therapy.

- Tailor treatment based on individual side-effect profiles and patient preference to optimise symptom control and quality of life.
- Review tolerability regularly during extended therapy.

➤ **Routes of Administration for Progestogens:**

- Oral progestogens (e.g., dienogest, norethisterone acetate, desogestrel, dydrogesterone)
- Depot medroxyprogesterone acetate (DMPA)
- Levonorgestrel-releasing intrauterine system (LNG-IUS)
- Etonogestrel-releasing subdermal implant (ENG)

➤ **Anti-Progestogens**

- Gestrinone is an effective treatment for endometriosis associated pain.
- Hirsutism and seborrhoea have been reported with its use.
- Anti-progestogens, though effective, are not included in the recommendations.

➤ **Danazol**

- Do not use oral danazol for endometriosis-associated pain unless no other medical therapy is available.
- Recognize that use of oral danazol is associated with significant androgenic side effects, including acne, oedema, vaginal spotting, weight gain, muscle cramps, deepening of voice, increase in facial hair.
- Danazol vaginal ring may be used effectively.

5.4.3 GnRH Agonists

➤ **Efficacy**

- Offer GnRH agonists to reduce endometriosis-associated pain
 - GnRH agonists are more effective than placebo.
 - No specific GnRH agonist is superior to another.

- Efficacy does not differ by route of administration (intramuscular, subcutaneous, intranasal).
- Evidence is limited regarding optimal dose and duration.

➤ **Safety and Side-Effects**

- Inform patients about common side effects, including hot flushes, vaginal dryness, headache, decreased libido, weight gain and acne.
- Recognize that long-term GnRH agonist use may lead to reduced bone mineral density (BMD).
- Consider GnRH agonists as second-line therapy due to its side effect profile and long-term effect on BMD.
- Use with caution in young women and adolescents.

➤ **Add-Back Therapy**

- Prescribe add-back therapy when using GnRH agonists longer than 6 months.
- Inform patients that add-back therapy does not reduce efficacy of GnRH agonists for endometriosis associated pain.
- Consider combined hormonal add-back therapy to prevent bone loss and hypoestrogenic symptoms.
- Options for add-back therapy include:
 - Progestin monotherapy (norethisterone/ norethindrone acetate NETA)
 - Estrogen-progestin combinations
 - Selective estrogen receptor modulators
 - Bisphosphonates
 - Tibolone
 - Testosterone
- The choice of add-back therapy should be guided by patient profile, patient preference, cost and availability.

5.4.4 GnRH Antagonists

➤ Efficacy

- Consider oral GnRH antagonists (e.g., elagolix, relugolix, linzagolix) for pain reduction.
 - GnRH antagonists are effective orally in relieving endometriosis associated pain.
 - Pain reduction may occur within one month.
 - Higher doses may increase efficacy.
 - Dose can be titrated based on clinical observations.
 - No specific GnRH antagonist can be recommended over another.
 - Evidence is limited regarding optimal dose, duration and need for add-back therapy.

➤ Safety and Side-Effects

- Inform patients about common side effects, including hot flashes, headache and nausea.
- Recognize potential impact on bone mineral density.
- Use with caution in young women and adolescents.
- Balance efficacy against side effects and long-term safety.

5.4.5 Aromatase Inhibitors

➤ Efficacy

- Recognize that aromatase inhibitors (e.g., letrozole, anastrozole) can reduce endometriosis-associated pain when combined with other hormonal therapy.
 - Aromatase inhibitors suppress all three sites of estrogen production (eutopic endometrium, ectopic endometrium and adipose tissues) when compared with GnRH agonists.
 - Evidence is limited and based mainly on small studies.
 - Letrozole combined with progestogens or GnRH analogues may reduce pain.
 - Superiority over other hormonal treatments has not been clearly demonstrated.

- Long-term efficacy data are lacking.

➤ **Safety and Side-Effects**

- Inform patients about hypoestrogenic side effects, including vaginal dryness, hot flushes and reduced bone mineral density.
- Recognize potential effects on ovulation and risk of multiple pregnancy if not adequately suppressed.
- Monitor bone health during treatment.
- Reserve aromatase inhibitors for women with pain refractory to other medical or surgical treatments.
- Use only after other options have been exhausted.
- Use shared decision-making and counsel carefully regarding risks and limited evidence.

5.5 Surgical Treatment

5.5.1 General Principles

- Offer surgical treatment as one of the options to reduce endometriosis-associated pain.
 - Surgery aims to remove endometriotic lesions and divide adhesions.
 - Surgical techniques include excision, ablation/vaporisation and adhesiolysis.
 - Surgery improves quality of life, especially pain, and may also improve mental health and sexual function.
- Use laparoscopy as the preferred surgical approach.
- Robotic-assisted surgery has a role in the management of deep endometriosis, however, current evidence shows perioperative outcomes comparable to conventional laparoscopy.
- Refer to a centre of expertise if relevant laparoscopic skills are not available.
- **Technical guidance on specific surgical techniques for endometriosis is not included in the scope of this guideline.**

5.5.2 Safety

- Inform patients that laparoscopic surgery is generally safe when performed by experienced surgeons.
- Recognize that laparoscopy is associated with shorter recovery and less postoperative pain compared with open surgery.
- Use shared decision-making when discussing surgical management.
- Balance expected benefits against surgical risks and alternative medical options.

5.5.3 Ablation versus Excision of Endometriosis

- When performing surgery, consider excision rather than ablation to reduce endometriosis-associated pain.
 - Existing literature indicates that surgical removal (cystectomy) is generally effective for reducing pain, particularly in severe cases.
 - Preferably perform surgical excision for deep endometriosis lesions.
 - Complete lesion removal cannot be ensured with ablative techniques.
- Use surgical expertise and lesion characteristics to guide choice of technique.
- Discuss potential benefits and risks of each approach with the patient.

5.5.4 Surgery for Superficial Peritoneal Endometriosis

- Superficial peritoneal endometriosis (SPE) may occur alone or alongside ovarian endometriomas and deep endometriosis.
- Recognize that no trials specifically evaluate surgery for SPE alone.
- Discuss uncertainty of evidence when counselling patients with suspected isolated SPE.

5.5.5 Surgical Interruption of Pelvic Nerve Pathways

- Laparoscopic uterosacral nerve ablation (LUNA) is not recommended as an adjunct to conventional laparoscopic surgery.
- Presacral neurectomy (PSN) may benefit selected patients with midline pain but requires advanced surgical skill and carries higher risk of adverse effects.

- Recognize that the role of surgical interruption of pelvic nerve pathways in the era of modern radical excision of deep endometriosis remains uncertain.

5.5.6 Surgery for Ovarian Endometrioma

- There are no RCTs comparing cystectomy with no treatment for pain relief in women with endometrioma.
- Perform laparoscopic ovarian cystectomy instead of drainage and coagulation for ovarian endometriotic cyst of size ≥ 3 cm.
 - Cystectomy reduced recurrence of dysmenorrhea and dyspareunia.
 - Cyst recurrence was lower after cystectomy.
 - Need for further surgery and non-menstrual pain were less common after cystectomy.
- Consider cystectomy or CO2 laser vaporisation for ovarian endometriomas
 - Higher recurrence at 12 months after laser vaporisation.
 - Similar recurrence rates at 60 months.
 - Shorter time to recurrence after laser.
- Minimise ovarian damage during surgery.
- Surgery may impair ovarian reserve, particularly in bilateral or recurrent cases. Ovarian reserve should be carefully considered before surgery, especially in young patients and patients with subfertility.
- When planning surgery for endometriosis in patients with fertility concerns, consider cyst drainage for symptom management prior to assisted reproductive techniques, and reserve cystectomy for after completion of fertility treatment, if required.
- Sclerotherapy may be considered as an alternative minimally invasive option in selected cases.
- Women with ovarian endometrioma and pain often have additional disease, including deep endometriosis. This should be considered during surgical planning.

5.5.7 Surgery for Deep Endometriosis

- Deep endometriosis extends beneath the peritoneum. It may affect:
 - Uterosacral ligaments

- Pelvic side walls
- Rectovaginal septum
- Vagina
- Bowel
- Bladder
- Ureter
- Laparoscopic excision of lesions is performed when surgery is chosen.

5.5.8 Bowel Endometriosis

- Bowel involvement occurs in 5–12% of women with endometriosis.
- About 90% affects the rectum or sigmoid colon. Small bowel, appendix, and caecum are less common.
- Accurate preoperative assessment of location and extent is essential.
- Surgical options include:
 - Conservative surgery: Shaving and Discoid resection
 - Segmental bowel resection.
- Surgery for colorectal endometriosis should be multidisciplinary.
- Patients should be counselled extensively regarding risk of significant complications of surgery for bowel endometriosis.
- Recurrence rates ranged from 5–25%. Symptomatic recurrence rates were higher than histological recurrence rates.
- A minimally invasive approach is preferred.
- Radical removal of lesions improves pain and may improve fertility.
- Patients should be referred to specialised centres if necessary.

5.5.9 Uterosacral Ligaments and Vaginal Endometriosis

- These lesions can often be diagnosed on clinical examination.
- A vagino-laparoscopic approach for excision showed significant symptom improvement, with few complications.

- Because of heterogeneous techniques and populations, no firm recommendation on specific surgical techniques can be made.

5.5.10 Cul-de-sac Endometriosis

- Significant pain reduction was reported following laparoscopic excision (Douglasectomy).
- Women undergoing concurrent hysterectomy also improved, but benefits varied between groups.

5.5.11 Bladder Endometriosis

- Treatment usually consists of excision (partial cystectomy or shaving).
- Surgical excision showed significant pain improvement with low complication rates and low recurrence rates.

5.5.12 Ureter Endometriosis

- Management options include:
 - Ureterolysis (most common).
 - Segmental ureteric resection with end-to-end anastomosis.
 - Ureteroneocystostomy.
- A conservative approach (ureterolysis) is appropriate in most cases.
- Surgery improves pain and quality of life in women with hydronephrosis or bladder involvement.

5.6 Hysterectomy for Endometriosis-Associated Pain

5.6.1 General Principles

- Hysterectomy (with or without oophorectomy) may be considered in women who no longer wish to conceive and who failed conservative treatment.
 - Hysterectomy reduces endometriosis-associated pain in many patients.
 - When performed, a total hysterectomy (removal of uterus and cervix) is preferred.

- Patients undergoing hysterectomy are less likely to require further surgery, compared to those who undergo conservative surgery.
- Inform patients that hysterectomy (with or without oophorectomy) may not cure symptoms in some patients, either due to residual disease or due to central sensitization.
- Hysterectomy with ovarian conservation was reported to have a 6-fold development of recurrent pain and an 8.1 times greater risk of re-operation.
- Oophorectomy must be balanced against effects of early menopause, long-term health risks, as well as the need for hormone replacement therapy.

5.7 Medical Therapies Adjunct to Surgery in Endometriosis

5.7.1 General Principles

- Distinguish adjunctive short-term (<6 months) hormone treatment after surgery from long-term (>6 months) hormone treatment.
 1. Short-term therapy is aimed at improving immediate surgical outcomes.
 2. Long-term therapy is aimed at secondary prevention of recurrence
- Therapies to improve immediate surgical outcomes will be discussed in this chapter.
- Recommendations for secondary prevention will be discussed separately.

5.7.2 Preoperative Medical Treatment

- Do not prescribe preoperative hormone therapy solely to improve immediate surgical outcomes for pain in women with endometriosis.
 - Evidence shows no benefit in pain, dysmenorrhea, dyspareunia, or disease recurrence.
- Consider short-term preoperative medical treatment with GnRH agonists only if it is needed to manage pain in the waiting period before surgery, not as a means to improve surgical outcomes.
- Recognize that in clinical practice, preoperative therapy:
 - May facilitate surgery by reducing inflammation, vascularisation, and adhesions, though controlled studies do not support this.

- May obscure dissection planes between ovarian tissue and the cyst wall, potentially increasing surgical difficulty.
- The decision to use preoperative therapy should be individualised, weighing potential benefits against the risk of complicating surgery.

5.7.3 Postoperative Medical Treatment

- Consider offering postoperative hormone treatment to improve immediate surgical outcomes for pain in women with endometriosis who do not desire immediate pregnancy.
- Ensure patients are informed about the aim of adjunctive hormone therapy—whether for short-term pain management or long-term prevention of recurrence.
- Offer postoperative hormone therapy if the goal is short-term improvement in pain and the patient is not attempting conception.
- Inform patients that there is only a very moderate benefit of postoperative hormone therapy (within 6 months after surgery) if this treatment is prescribed with the sole aim of improving the outcome of surgery
- Options for treatment include:
 - GnRH agonists
 - Progestogens
 - Combined hormonal contraceptive pills
 - Levonorgestrel-releasing intrauterine system (LNG-IUS)
 - LNG-IUS may reduce dysmenorrhea and non-cyclical pelvic pain, with fewer patients experiencing recurrent dysmenorrhea at 12 months.
- Hormone therapy may also be prescribed for other indications, such as contraception or as part of secondary prevention.

5.8 Medical versus Surgical Treatment for Endometriosis

- Inform women that there is no conclusive evidence that medical therapy or surgery is more effective for pain relief in endometriosis.
- Explain that surgery may provide rapid pain relief but carries a risk of complications and recurrence.

- Explain that medical treatment avoids general anaesthesia and hospitalisation but may cause short- and long-term side effects and often requires prolonged use.
- Use a shared decision-making approach. Consider individual preferences, side effects, likely efficacy, costs, and availability when choosing between hormonal and surgical treatment.

5.9 Non-Medical Management Strategies in Endometriosis

5.9.1 General Principles

- Recognize that evidence for non-medical strategies in endometriosis is limited.
- Acknowledge that many women seek non-pharmacological and non-surgical approaches alongside or instead of medical and surgical treatments.

5.9.2 Multidisciplinary Care

- Consider a multidisciplinary approach for women with persistent endometriosis-associated symptoms.
- Multidisciplinary care may include:
 - Pain specialists
 - Physiotherapy
 - Psychological support
 - Sexual health counselling
- Discuss with patients, non-medical strategies to address quality of life and psychological well-being in women living with endometriosis.
- No recommendations can be made for any specific non-medical intervention (nutrition, electrotherapy, acupuncture, physiotherapy, exercise, and psychological interventions) to reduce pain, as the potential benefits and harms are unclear.
- Offer referral to specialist pain management services with expertise in complex abdomino-pelvic pain when appropriate.
- Discuss access to peer and patient support groups where available.
- Use shared decision-making to align non-medical options with individual needs, patient preferences and available local resources.

6.0 Treatment of Endometriosis-Associated Infertility

6.1 General Principles

- Engage both partners in comprehensive counselling and shared decision-making.
- Offer referral to registered fertility centers.
- Ensure initial counselling by the primary contact Gynecologist.
- Counsel women regarding the impact of endometriosis on fertility and pregnancy outcomes.

6.2 Medical Treatment

- Do not prescribe ovarian suppression therapy to improve fertility.
- Do not use hormonal therapy as an adjunct to ART to improve pregnancy rates.
- Do not prescribe postoperative hormone suppression to enhance future pregnancy rates.
- Offer postoperative hormonal therapy to improve pain control in women who are not attempting immediate conception.
- Inform patients that short-term postoperative hormone therapy does not negatively affect future fertility.

6.3 Surgical Treatment

- Offer operative laparoscopy for infertility in women with rASRM stage I/II endometriosis.
- Consider operative laparoscopy for ovarian endometrioma-associated infertility.
 - Offer laparoscopic ovarian cystectomy with excision of the cyst wall, or laparoscopic drainage and ablation of endometrioma larger than 3cm, as both approaches improve the chance of spontaneous pregnancy.
 - Counsel the patient of the potential impact on ovarian reserve.

- Inform patients that drainage and ablation may preserve ovarian reserve better than cystectomy.
- When planning surgery for endometriosis in patients with fertility concerns, consider cyst drainage for symptom management prior to assisted reproductive techniques, and reserve cystectomy for after completion of fertility treatment, if required.
- Surgery for endometrioma prior to ART can be considered to improve endometriosis-associated pain or accessibility of follicles.
- Inform patients that surgery may negatively impact ovarian reserve.
- Consider using the Endometriosis Fertility Index (EFI) to identify patients who may benefit from ART after surgery.
- Ensure completion of other fertility investigations, including semen analysis.
- Individualize decision-making for deep endometriosis surgery based on:
 - Severity of pain
 - Age
 - Patient preference
 - Previous surgeries
 - Other infertility factors
 - Ovarian reserve
 - Estimated EFI

6.4 Medically Assisted Reproduction

6.4.1 Intrauterine Insemination (IUI)

- Consider IUI with ovarian stimulation for women with rASRM stage I/II endometriosis-associated infertility.
- Offer IUI with ovarian stimulation instead of expectant management or IUI alone to improve pregnancy rates.
- Consider IUI with ovarian stimulation in selected women with rASRM stage III/IV disease with tubal patency.

6.4.2 Assisted Reproductive Technology (ART)

- Offer ART in women with:
 - Failed prior treatments
 - Low EFI
 - Compromised tubal function
- Allow ART protocols to be determined by the treating fertility center.
- Consider antibiotic prophylaxis during oocyte retrieval in women with endometriomas to reduce abscess risk.
- Inform women that ART is safe and not associated with increased endometriosis recurrence.

6.5 Non-Medical Treatments

- Inform patients that current evidence does not support improvement in fertility outcomes with any of the following non-medical therapies:
 - Nutritional therapy
 - Traditional medicine
 - Acupuncture
 - Cupping therapy
 - Electrotherapy
 - Physiotherapy
 - Exercise
 - Psychological interventions
- Do not offer non-medical therapies solely to improve fertility, due to lack of evidence.

6.6 Fertility Preservation

- Discuss fertility preservation in women with extensive ovarian endometriosis.
- Explain risks and benefits clearly before proceeding.
- Individualize decision-making based on ovarian reserve and reproductive goals.

7.0 Recurrence and Secondary Prevention of Endometriosis

7.1 Definition of Recurrence

- Consider recurrence when there is:
 - Return of pain (dysmenorrhea, dyspareunia, pelvic pain).
 - Clinical findings (tender nodules, fibrotic areas).
 - Radiologic evidence of lesions.
 - Surgically confirmed lesions.
 - Repeat rise in CA-125 after surgery.

Classify Recurrence as:

1. Symptom-based suspected recurrence
 - Consider when symptoms recur without imaging or surgical confirmation.
 2. Imaging-based suspected recurrence
 - Consider when lesions are detected on imaging, with or without symptoms.
 3. Laparoscopically proven recurrence
 - Define when visual lesions are seen at laparoscopy without histologic confirmation.
 4. Histologically proven recurrence
 - Define when lesions are visually identified and biopsy confirmed.
- Recognize that recurrence rates range widely (0–89.6%) and may be attributed to different definitions, the length of follow-up, the type and stage of disease, the type of surgery and the postoperative medical treatment

7.2 Risk Assessment for Recurrence

7.2.1 Patient- and Disease-Related Factors

- Consider increased risk in patients with:
 - Positive family history
 - Young age
 - Prior ovarian stimulation
 - High BMI
 - No pregnancy after surgery
 - Large endometrioma (>5 cm)
 - Advanced-stage disease
 - Severe preoperative pain
 - High CA-125

7.2.2 Surgery-Related Factors

- Consider increased risk when there are:
 - Extensive adhesions.
 - Radical surgery.
 - Positive surgical margins.

7.2.3 Identifying Recurrence

- Identify high-risk patients to guide postoperative preventive therapy.
- Use imaging as first-line when recurrence is suspected.
- Do not use repeated surgery as first-line assessment, as it may increase adhesions and recurrence.

7.3 Prevention of Recurrence or Secondary Prevention

- Define secondary prevention as prevention of pain symptoms or lesion recurrence more than 6 months after surgery.
- Consider bowel lesions, adhesions, and adenomyosis during management planning.
- Maximize medical therapy before offering repeat surgery.

7.3.1 Surgical Prevention Strategies

- Perform ovarian cystectomy instead of drainage and electrocoagulation for secondary prevention where surgery is indicated for endometrioma.
- Ensure meticulous surgical technique to minimize ovarian damage.
- Use oxidised regenerated cellulose (ORC, Surgical) where available during ovarian cystectomy or drainage for endometrioma, as its use has shown reduced recurrence rates.
- Discuss with patients the impact on ovarian reserve before surgery, especially in patients with bilateral endometriomas and recurrent endometriomas.

7.3.2 Medical Prevention Strategies

- Distinguish between:
 - Short-term (<6 months) postoperative therapy aimed at improving immediate outcomes of surgery.
 - Long-term therapy (>6 months) after surgery for prevention of recurrence (secondary prevention).
- Offer postoperative hormonal therapy after conservative surgery, especially if pregnancy is not desired.
- Medical treatment after conservative surgery for endometriosis can be in the form of combined hormonal contraceptive pill, progestogens, or GnRH agonist

7.3.3 First-Line Options

- Offer combined hormonal contraceptives (CHCs) for 18-24 months
- Offer progestogens for 18-24 months

7.3.4 Alternative Options

- Offer LNG-IUS (52 mg) or CHCs for 18–24 months for secondary prevention of dysmenorrhea.
- Consider Dydrogesterone (10–20 mg/day) from day 5–25 for 3–6 months to improve pain symptoms.
- Consider Dienogest or GnRH agonists (for 6 months) for secondary prevention of pelvic pain after laparoscopy.
- Consider GnRH agonists when first-line therapy fails or is contraindicated.
- Offer long-term hormonal therapy after ovarian endometrioma surgery if conception is not immediately desired.
- Consider long-term hormone therapy for deep endometriosis.
- Use continuous or cyclic OCP regimens according to patient preference (similar efficacy).
- Inform patients with endometriosis undergoing ART, that ART is safe and does not appear to increase the risk of endometriosis recurrence.

7.4 Treatment of Recurrent Endometriosis

7.4.1 Medical Treatment

- Offer any hormonal therapy (CHC, Progestogens, LNG-IUS, GnRH analogues) for recurrent endometriosis.
- Ensure evaluation for alternative causes of pain (e.g., adenomyosis, pelvic floor dysfunction), especially if symptoms recur early after surgery.
- Discuss with the patient regarding the benefits, risks and side effects of the different hormone and surgical treatments
- Take into account the availability and cost of different therapies when formulating a long-term treatment plan for secondary prevention.
- Where available, consider GnRH agonists or dienogest for treatment of recurrent endometriosis, as evidence supports their efficacy.

7.4.2 Surgical Treatment

- Do not routinely offer repeat surgery without prior medical therapy optimisation.
- Recognize increased risk to ovarian reserve with repeat surgery for ovarian endometrioma.
- Counsel patients regarding risk of greater removal of healthy ovarian tissue and potential decline in AFC with repeat surgery.

8.0 Endometriosis in Adolescents

8.1 Dysmenorrhea in Adolescents

- Recognize that dysmenorrhea is the most common menstrual symptom in adolescents, affecting 50–90%.
- Consider primary dysmenorrhea as the most likely diagnosis when painful menstruation occurs in the absence of pelvic pathology, particularly after ovulatory cycles are established (typically 6–12 months after menarche).
- Use empiric treatment with nonsteroidal anti-inflammatory drugs (NSAIDs) and/or hormonal therapy as first-line management for presumed primary dysmenorrhea.
- Ensure reassessment within 3–6 months of initiating empiric therapy.
- Investigate for secondary causes if symptoms persist or do not respond adequately to NSAIDs and/or hormonal therapy within 3–6 months.

8.2 Secondary Dysmenorrhea and Endometriosis

- Consider secondary dysmenorrhea when menstrual pain is caused by underlying pelvic pathology or medical conditions.
- Recognize endometriosis as the leading cause of secondary dysmenorrhea in adolescents.
- Ensure early evaluation, as diagnosis of endometriosis in adolescents is often delayed by 7–12 years after symptom onset.

8.3 Differential Diagnosis of Secondary Dysmenorrhea

- Ensure evaluation to exclude other causes of secondary dysmenorrhea, including:
 - Obstructive anomalies
 - Hymenal anomalies
 - Vaginal anomalies
 - Müllerian anomalies (e.g., obstructed hemivagina, cervical stenosis)

- Adenomyosis, which may occur in adolescents and frequently coexists with endometriosis.
- Other pelvic pathologies, including:
 - Ovarian cysts
 - Uterine polyps
 - Leiomyomata
 - Pelvic inflammatory disease
 - Pelvic adhesions
- Suspect secondary dysmenorrhea if any of the following are present:
 - Severe dysmenorrhea immediately after menarche
 - Progressive worsening of menstrual pain
 - Abnormal uterine bleeding
 - Mid-cycle or acyclic pelvic pain
 - Lack of response to empiric NSAIDs and/or hormonal therapy

8.4 Risk Assessment

- Ensure detailed clinical history to identify risk factors.
- Consider increased risk in adolescents with:
 - Family history of endometriosis in first-degree relative (7 to 10 fold increased risk)
 - Menstrual factors
 - Early menarche (<12 years)
 - Short menstrual cycles
 - Genital tract anomalies
 - Obstructive outflow anomalies associated with retrograde menstruation

8.5 Predictive Clinical Markers

- Consider increased suspicion for endometriosis when the following markers are present:
 - Chronic pelvic pain (cyclic or non-cyclic)
 - Dysmenorrhea resistant to NSAIDs and/or oral contraceptives
 - Severe dysmenorrhea
 - Dyspareunia
 - Dyschezia during menstruation
 - Pain interfering with school attendance or daily activities
 - History of benign ovarian cysts
 - Use of oral contraceptives for dysmenorrhea before age 18 (associated with later diagnosis of deep infiltrating endometriosis)

8.6 Clinical Presentation

- Consider endometriosis in adolescents presenting with:
 - Dysmenorrhea (most common symptom)
 - Chronic pelvic pain, including non-menstrual or acyclic pain
 - Constant, intermittent, cyclic, or acyclic pain patterns
- Consider associated gastrointestinal and urinary symptoms, including:
 - Nausea
 - Vomiting
 - Diarrhea
 - Dysuria
- Ensure heightened suspicion when pelvic pain is associated with nausea.

8.7 Clinical Examination

8.7.1 Primary Dysmenorrhea

- Do not routinely perform pelvic examination when clinical history is consistent with primary dysmenorrhea.
- Offer pelvic examination only if clinically indicated, such as suspicion of sexually transmitted infection.

8.7.2 Suspected Secondary Dysmenorrhea

- Offer pelvic examination to evaluate for:
 - Obstructive anomalies
 - Pelvic masses
 - Pelvic floor disorders
- Ensure examination is conducted with sensitivity and informed consent.
- Use transabdominal or transrectal ultrasound as an alternative in adolescents who are not sexually active or decline vaginal examination.
- Ensure shared decision-making involving the adolescent and caregiver regarding examination approach.

8.8 Psychological and Quality of Life Assessment

- Ensure assessment of psychological and social impact.
- Consider increased risk of:
 - Anxiety
 - Depression
 - Social withdrawal
- Assess impact on quality of life, including:
 - School absenteeism
 - Academic performance
 - Social functioning

- Ensure multidisciplinary care, including psychological support when chronic pain or central sensitization is suspected.

8.9 Investigations

8.9.1 Laboratory Testing

- Do not use serum biomarkers (e.g., CA-125) to diagnose or exclude endometriosis, due to poor diagnostic performance in adolescents.

8.9.2 Imaging

➤ Ultrasound

- Use ultrasound as the initial imaging modality.
- Use transabdominal ultrasound as the preferred initial approach in adolescents.
- Use transvaginal ultrasound only when appropriate and acceptable to the adolescent.
- Consider transrectal ultrasound as an alternative when appropriate.
- Ensure ultrasound evaluation for:
 - Ovarian endometriomas
 - Obstructive Müllerian anomalies
- Recognize that ultrasound has limited sensitivity for peritoneal endometriosis.

➤ Magnetic Resonance Imaging

- Consider MRI when further delineation is required for:
 - Müllerian anomalies
 - Deep infiltrating endometriosis
- Do not use MRI as an initial screening tool, due to limited cost-effectiveness.
- Ensure understanding that normal ultrasound or MRI does not exclude endometriosis.

8.10 Treatment

8.10.1 Treatment Goals

Ensure management aims to:

- Relieve symptoms
- Suppress disease progression
- Preserve future fertility

8.10.2 Medical Management

➤ **First-Line Treatment**

- Use NSAIDs as first-line therapy.
- Offer hormonal suppression, including:
 - Combined oral contraceptives (cyclic or continuous)
 - Progestin-only pills
 - Levonorgestrel-releasing intrauterine system (LNG-IUS), where appropriate

➤ **Second-Line Treatment**

- Consider GnRH agonists when symptoms are refractory to first-line treatment.
- Limit GnRH agonist therapy to a maximum of 12 months.

➤ **Add-back Therapy**

- Ensure add-back therapy (estrogen and/or progestin) is prescribed along with GnRH agonists.
- Do not use GnRH agonists without add-back therapy, due to increased risk of bone mineral density loss and hypoestrogenic symptoms in adolescents.

8.10.3 Surgical Management

➤ Indications

- Consider laparoscopy when:
 - Symptoms persist despite adequate medical treatment
 - Imaging is negative but clinical suspicion remains high
- Recognize laparoscopy as the gold standard for diagnosis.

➤ Surgical Technique

- Ensure surgeons recognize adolescent lesion appearance, which may be:
 - Clear (vesicular)
 - Red rather than typical adult "powder burn" lesions.
- Use conservative surgical approaches, including:
 - Excision
 - Ablation
 - Coagulation of visible implants
- Do not offer peritoneal stripping routinely, due to increased adhesion risk.
- Do not offer hysterectomy or oophorectomy in adolescents, except in exceptional circumstances.

➤ Postoperative Management

- Offer postoperative hormonal suppression to reduce recurrence risk.
- Ensure combined surgical and medical management, as surgery alone is associated with high recurrence rates.

8.11 Fertility Preservation and Counseling

- Ensure counseling regarding potential impact of endometriosis and ovarian surgery on ovarian reserve.
- Consider fertility preservation options, including oocyte cryopreservation, particularly in adolescents with:
 - Bilateral endometriomas
 - Risk of repeated ovarian surgery
- Ensure individualized counseling, recognizing that evidence for fertility preservation in adolescents is evolving.

9.0 Management of Postmenopausal Women with Endometriosis

9.1 Risk of Malignancy and Initial Assessment

- Acknowledge the uncertainty regarding the risk of malignancy in postmenopausal women with endometriosis.
- Ensure that any postmenopausal woman presenting with a pelvic mass undergoes appropriate evaluation.
- Use national oncology guidelines to guide the work-up and management of suspected malignancy.

9.2 Surgical Management

- Consider surgical treatment for postmenopausal women with endometriosis who present with pain.
- Consider laparoscopy to:
 - Treat pain symptoms.
 - Confirm the diagnosis of endometriosis histologically.
- Consider surgical management particularly in women with endometrioma, given the reported proportion of concurrent malignancy.
- Ensure that patients are counselled regarding the potential benefits (pain relief and possible reduction in future malignancy risk) and the potential surgical risks.
- Inform patients that although specific complication data in postmenopausal women are limited, surgery for endometriosis is generally considered relatively safe.

9.3 Medical Management of Endometriosis-Associated Pain

- Consider aromatase inhibitors for postmenopausal women with endometriosis-associated pain, especially when surgery is not feasible or is contraindicated.
- Ensure shared decision-making when discussing medical therapy, acknowledging the limited evidence base.

9.4 Menopausal Hormone Therapy (MHT)

9.4.1 Use of Combined MHT

- Consider combined menopausal hormone therapy (estrogen-progestogen) for the treatment of menopausal symptoms in women with a history of endometriosis (after natural or surgical menopause).
- Offer combined estrogen-progestogen therapy to women with a history of endometriosis who undergo surgical menopause, at least until the age of natural menopause.
- Ensure patients are counselled regarding:
 - The benefits of MHT for vasomotor symptoms, urogenital atrophy, and quality of life.
 - The limited evidence regarding recurrence risk.
 - The small number of reported malignancy cases with combined regimens.

9.4.2 Estrogen-Only Therapy

- Do not offer estrogen-only regimens for the treatment of vasomotor symptoms in postmenopausal women with a history of endometriosis.
- Avoid unopposed estrogen therapy due to the potential increased risk of malignant transformation.

9.5 Long-Term Health Considerations

- Ensure clinicians are aware that women with endometriosis who undergo early bilateral salpingo-oophorectomy have increased risks of:
 - Reduced bone density
 - Dementia
 - Cardiovascular disease
- Recognize that women with endometriosis have an increased baseline risk of cardiovascular disease, irrespective of surgical menopause status.
- Consider cardiovascular risk assessment and bone health monitoring as part of long-term follow-up care.

10.0 Extra-pelvic Endometriosis (Abdominal Wall, Umbilical, Inguinal, Thoracic and Diaphragmatic)

10.1 Abdominal Wall, Umbilical and Inguinal Endometriosis

10.1.1 Risk Factors and Clinical Suspicion

- Consider abdominal wall endometriosis in women presenting with a painful abdominal wall nodule, particularly with cyclical symptoms.
- Ensure careful history taking in women with prior gynaecological surgery, especially:
 - Caesarean section
 - Laparoscopy
 - Abdominal hysterectomy
- Recognise that the mean interval between index surgery and presentation may be several years.
- Consider Caesarean section scar endometriosis as the most common form of abdominal wall endometriosis.
- Consider umbilical or episiotomy scar endometriosis in women presenting with cyclical umbilical or perineal nodules.

10.1.2 Imaging and Diagnosis

- Use ultrasonography as the first-line imaging modality for evaluation of focal abdominal or inguinal wall thickening.
- Ensure that imaging assesses:
 - Extent of the lesion
 - Relationship to surrounding structures
 - Presence or exclusion of abdominal wall hernia

- Consider magnetic resonance imaging (MRI), particularly in younger patients, due to:
 - Superior soft tissue characterisation
 - Absence of ionising radiation
 - Better delineation between muscle and subcutaneous tissue
- Consider computed tomography (CT) when:
 - The diagnosis is uncertain
 - Further delineation of lesion extent is required
 - Alternative diagnoses (e.g., hernia, abscess, haematoma, soft tissue tumour) need exclusion
- Use intravenous contrast with CT when appropriate to improve diagnostic performance.
- Recognise that imaging findings may vary depending on:
 - Phase of menstrual cycle
 - Chronicity
 - Degree of bleeding and inflammation
- Consider performing imaging during menstruation when scar endometriosis is suspected. Lesions may become more conspicuous during this phase.
- Acknowledge that there is insufficient comparative evidence to recommend one imaging modality as superior for all cases.

10.1.3 Management of Abdominal Wall, Umbilical and Inguinal Endometriosis

➤ **Surgical Treatment**

- Offer complete surgical excision as the preferred treatment when technically feasible.
- Ensure adequate surgical margins to reduce recurrence risk.
- Consider cosmetic outcomes, particularly in umbilical endometriosis.
- Consider a multidisciplinary approach for inguinal lesions due to proximity to:
 - Neural structures
 - Femoral vessels
- Inform patients about the risk of recurrence following excision.

➤ **Medical Treatment**

- Consider long-term hormonal therapy when:
 - Complete excision is not possible
 - Surgery is declined
 - Disease is multifocal or recurrent
- Use medical therapies according to principles applied in pelvic endometriosis, including:
 - Oral progestins
 - Gonadotropin-releasing hormone (GnRH) agonists
 - Combined oral contraceptives
- Consider high-intensity focused ultrasound (HIFU) as an alternative to surgery in selected patients, where expertise is available.

10.2 Thoracic and Diaphragmatic Endometriosis

10.2.1 Clinical Suspicion and Diagnosis

- Consider thoracic endometriosis syndrome (TES) in women presenting with cyclical thoracic symptoms occurring 24–72 hours around menstruation, including:
 - Cyclical shoulder pain
 - Cyclical spontaneous pneumothorax
 - Cyclical haemothorax
 - Cyclical haemoptysis
 - Catamenial cough
- Recognise that right-sided thoracic involvement is highly suggestive.
- Consider TES in cases of recurrent pneumothorax, particularly when temporally related to menses.
- Ensure histological confirmation where feasible.
- Use MRI for evaluation of suspected diaphragmatic endometriosis where available.

- Acknowledge that diagnosis may be challenging and symptoms may not initially be attributed to endometriosis.

10.2.2 Multidisciplinary Management

- Ensure that diagnosis and management of thoracic endometriosis are discussed in a multidisciplinary team (MDT).
- Refer patients to centres with expertise in extrapelvic endometriosis when available.
- Ensure collaboration with thoracic surgeons for cases requiring surgical intervention.

10.2.3 Medical Treatment

- Offer hormonal treatment (e.g., combined oral contraceptives or GnRH agonists) as first-line therapy in thoracic endometriosis.
- Inform patients about the potential for recurrence with hormonal therapy.
- Consider postoperative hormonal therapy following thoracic surgery to reduce recurrence risk.

10.2.4 Surgical Treatment

- Consider surgical management in cases of:
 - Recurrent pneumothorax
 - Recurrent haemothorax
 - Persistent haemoptysis
 - Failure of medical treatment
- Use video-assisted thoracoscopic surgery (VATS) as the preferred surgical approach where expertise is available.
- Consider pleurodesis, pleural abrasion, or pleurectomy in recurrent pneumothorax or haemothorax.
- Consider lobectomy or segmentectomy for persistent haemoptysis due to parenchymal lesions.
- Ensure intraoperative evaluation of the diaphragm for endometriotic lesions.
- Consider evaluation and treatment of concomitant pelvic endometriosis if diaphragmatic disease is identified.

10.2.5 Bilateral Salpingo-Oophorectomy (BSO)

- Consider bilateral salpingo-oophorectomy in women with:
 - Recurrent catamenial pneumothorax
 - No future fertility plans
 - Refusal of or contraindication to thoracic surgery
- Ensure thorough counselling regarding:
 - Consequences of surgical menopause
 - Long-term health implications

10.2.6 Additional Recommendations

- Ensure clinicians are aware of symptoms suggestive of extrapelvic endometriosis.
- Consider cyclical pain as a key diagnostic feature.
- Use location-specific imaging and endoscopic investigations when clinically indicated.
- Acknowledge that evidence is limited and recommendations are largely based on low-quality data.
- Ensure shared decision-making with patients, discussing uncertainty, recurrence risk, and treatment alternatives.

11.0 Management of Asymptomatic Endometriosis

11.1 Incidental Diagnosis

- Inform and counsel women about incidental findings of endometriosis detected on imaging or intra-operatively.
- Clearly document findings in the medical record.
Ensure results are communicated to the patient in understandable terms.

11.2 Medical and Surgical Management

- Do not offer surgical treatment for incidental endometriosis in asymptomatic women.
- Do not prescribe medical (hormonal) therapy for asymptomatic incidental disease.
- Inform patients that:
 - The risk of progression from minimal asymptomatic disease to symptomatic disease is low.
 - Surgical treatment may carry risks to adjacent anatomical structures.

11.3 Follow-Up

- Offer periodic clinical evaluation for asymptomatic women.
- Use ultrasound monitoring as part of follow-up when appropriate.
- Consider the type and location of the lesion when planning follow-up.
- Tailor surveillance to reduce risk of disease progression while avoiding unnecessary intervention.

12.0 Primary Prevention of Endometriosis

12.1 General Principles

- Inform women that the exact cause of endometriosis remains unknown.
- Explain that evidence-based preventive measures are limited.

12.2 Lifestyle Measures

- Advise a healthy lifestyle, including:
 - Regular physical activity
 - Well-balanced diet
 - Maintenance of healthy body weight
- Advise avoidance of alcohol intake to improve overall health.
- Inform women that a healthy lifestyle may improve general wellbeing and could potentially reduce risk, although definitive preventive evidence is lacking.

12.3 Hormonal Contraception

- Do not prescribe oral contraceptives solely for primary prevention of endometriosis.
- Inform women that current evidence does not show a strong protective association between oral contraceptive use and reduced risk of endometriosis.

12.4 Risk Factors and Counselling

- Recognize epidemiological risk factors, including:
 - Early menarche
 - Short menstrual cycle length
 - Long or heavy menstrual flow
 - Lean body habitus
 - Low gravidity or parity

- Inform women that these factors are associated with increased risk but are not modifiable in most cases.

12.5 Environmental Exposure

- Inform women that current evidence does not confirm a clear association between environmental pollutants and future risk of endometriosis.

12.6 Genetic Testing

- Do not offer genetic testing for suspected or confirmed endometriosis in routine clinical practice.
- Inform women that the genetic basis of endometriosis remains under investigation.

13.0 Endometriosis and Cancer Risk

13.1 General Cancer Risk

- Inform women that endometriosis is associated with a slightly increased risk of:
 - Ovarian cancer (particularly clear cell and endometrioid subtypes)
 - Breast cancer
 - Thyroid cancer
- Reassure patients that although relative risk is increased, the absolute overall cancer risk remains low.
- Recognize increased risk of ovarian and breast cancer in women with endometrioma, particularly with increasing age.

13.2 Oral Contraceptive Pills and Cancer Risk

- Offer hormonal therapy (COCPs or progestogens) for treatment of endometriosis-associated pain when indicated.
- Inform women that long-term treatment is often required due to recurrence of symptoms after discontinuation.

13.2.1 Cancer Risk with OCP Use

- Inform women that OCP use is associated with reduced risk of:
 - Ovarian cancer
 - Endometrial cancer
 - Colorectal cancer
- Inform women that OCP use is also associated with increased risk of:
 - Breast cancer
 - Cervical cancer
- Ensure clinicians discuss risks and benefits of prolonged hormonal therapy before initiation and during follow-up.

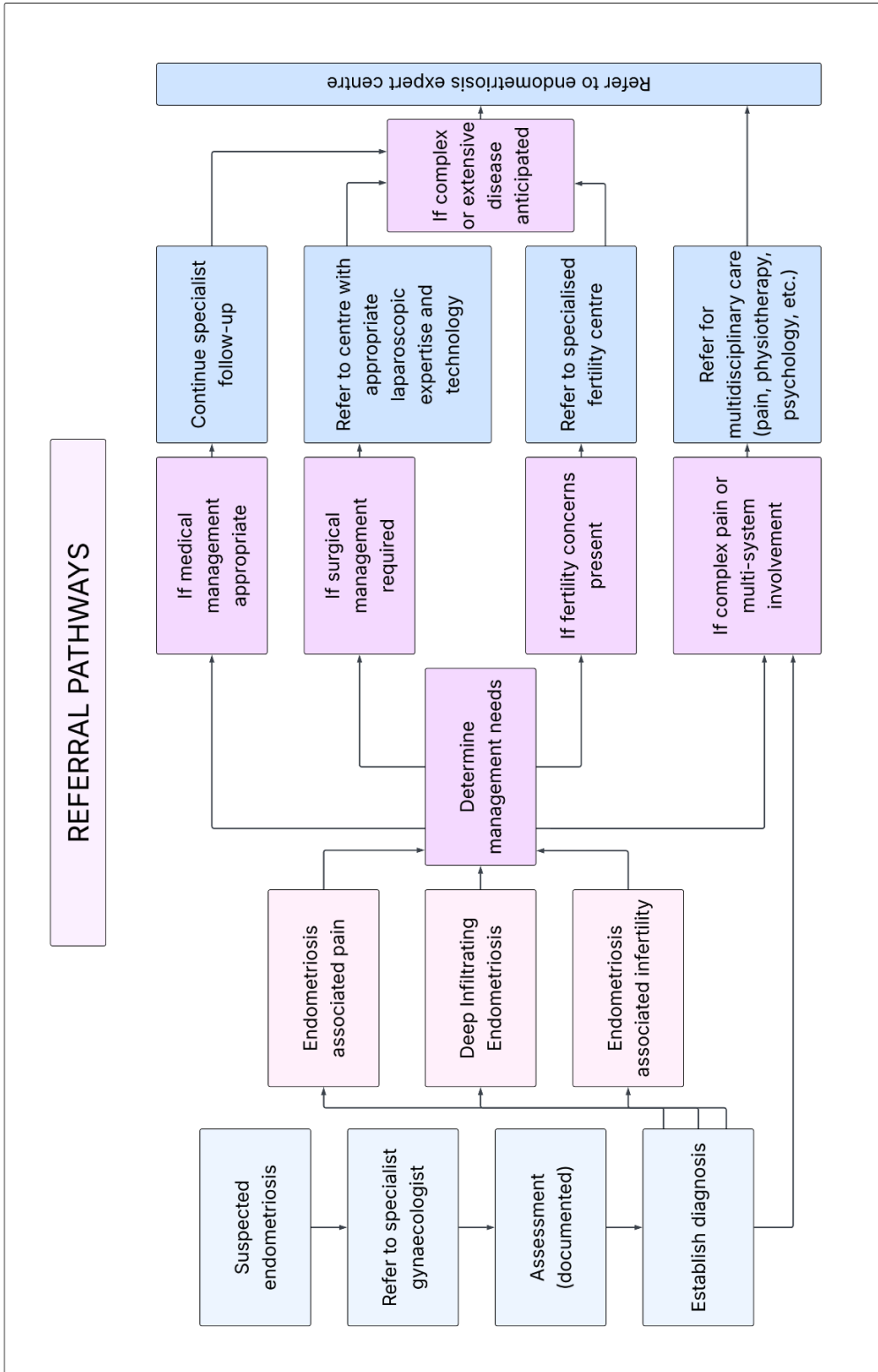
13.3 Role of CA-125 and Imaging

- Consider regular CA-125 measurement and/or ultrasound surveillance in women at high risk of ovarian cancer, including:
 - Strong family history of ovarian or breast cancer
 - Known germline mutations
- Do not offer routine CA-125 testing or ultrasound surveillance in women with endometriosis who are not at increased genetic or familial risk.

13.4 Surgery and Cancer Risk







- Do not perform additional cancer screening beyond standard population-based guidelines in women with endometriosis.
- Offer prophylactic bilateral salpingo-oophorectomy (BSO) in women with endometriosis who are at high risk of ovarian cancer (e.g., strong genetic risk).
- Do not recommend prophylactic BSO in women with endometriosis who have no additional ovarian cancer risk factors.
- Consider individualized cancer screening in women with additional risk factors such as:
 - Strong family history
 - Known pathogenic germline mutations
 - Personal history of cancer

14.0 Referral Pathway



15.0 Appendix

APPENDIX 1: Revised American Society for Reproductive Medicine (rASRM) staging system

<p>STAGE I (MINIMAL)</p> 	<p>STAGE II (MILD)</p> 	<p>STAGE III (MODERATE)</p> 
<p>PERITONEUM Superficial endo - 1-3cm -2</p> <p>R OVARY Superficial endo - < 1cm -1 Filmy adhesions - < $\frac{1}{3}$ -1 TOTAL POINTS $\frac{-1}{4}$</p>	<p>PERITONEUM Deep endo - > 3cm -6</p> <p>R OVARY Superficial endo - < 1cm -1 Filmy adhesions - < $\frac{1}{3}$ -1</p> <p>L OVARY Superficial endo - < 1cm $\frac{-1}{9}$ TOTAL POINTS $\frac{-1}{9}$</p>	<p>PERITONEUM Deep endo - > 3cm -6</p> <p>CULDESAC Partial obliteration -4</p> <p>L OVARY Deep endo - 1-3cm $\frac{-16}{26}$ TOTAL POINTS $\frac{-16}{26}$</p>
<p>STAGE III (MODERATE)</p> 	<p>STAGE IV (SEVERE)</p> 	<p>STAGE IV (SEVERE)</p> 
<p>PERITONEUM Superficial endo - >3cm -4</p> <p>R TUBE Filmy adhesions - < $\frac{1}{3}$ -1</p> <p>R OVARY Filmy adhesions - < $\frac{1}{3}$ -1</p> <p>L TUBE Dense adhesions - < $\frac{1}{3}$ -16*</p> <p>L OVARY Deep endo - < 1cm -4 Dense adhesions - < $\frac{1}{3}$ $\frac{-4}{30}$ TOTAL POINTS $\frac{-4}{30}$</p>	<p>PERITONEUM Superficial endo - >3cm -4</p> <p>L OVARY Deep endo - 1-3cm -32** Dense adhesions - < $\frac{1}{3}$ -8**</p> <p>L TUBE Dense adhesions - < $\frac{1}{3}$ $\frac{-8**}{52}$ TOTAL POINTS $\frac{-8**}{52}$</p> <p>*Point assignment changed to 16 **Point assignment doubled</p>	<p>PERITONEUM Deep endo - >3cm -6</p> <p>CULDESAC Complete obliteration -40</p> <p>R OVARY Deep endo - 1-3cm -16 Dense adhesions - < $\frac{1}{3}$ -4</p> <p>L TUBE Dense adhesions - > $\frac{2}{3}$ -16</p> <p>L OVARY Deep endo - 1-3cm -16 Dense adhesions - > $\frac{2}{3}$ $\frac{-16}{114}$ TOTAL POINTS $\frac{-16}{114}$</p>

Source: Endometriosis, Springer Nature Switzerland AG, 2022

APPENDIX 2: The #Enzian classification



#Enzian

(Classification of Endometriosis)

<p>PERITONEUM</p> <p>P Peritoneum</p> <p>Sum of all diameters</p> <p>P1 $\Sigma < 3$ cm</p> <p>P2 $\Sigma 3-7$ cm</p> <p>P3 $\Sigma > 7$ cm</p>	<p>OVARY</p> <p>O Ovary</p> <p>Sum of all diameters</p> <p>O1 $\Sigma < 3$ cm</p> <p>O2 $\Sigma 3-7$ cm</p> <p>O3 $\Sigma > 7$ cm</p>	<p>TUBE</p> <p>T Tubo-ovarian condition</p> <p>Adhesions</p> <p>Motility</p> <p>Patency test</p> <p>T1 Pelvic sidewall</p> <p>T2 Pelvic sidewall/ Uterus</p> <p>T3 Pelvic sidewall/ Uterus/ Bowel, USL</p>	<p>DEEP ENDOMETRIOSIS</p> <p>A Rectovaginal space, Vagina, Retrocervical area</p> <p>B Sacrotuberine liggs., Cardinal ligaments, Pelvic sidewall</p> <p>C Rectum</p> <p>F (.....) Location</p> <p>Diaphragm</p> <p>Lung</p> <p>Nerve</p>
<p>A1 < 1 cm</p> <p>A2 $1-3$ cm</p> <p>A3 > 3 cm</p>	<p>B1 < 1 cm</p> <p>B2 $1-3$ cm</p> <p>B3 > 3 cm</p>	<p>C1 < 1 cm</p> <p>C2 $1-3$ cm</p> <p>C3 > 3 cm</p>	<p>FA denomyosis</p> <p>FB bladder</p> <p>FI Intestinum</p> <p>FU Ureter</p>

P _____ / **O** _____ / **T** _____ / **A** _____ / **B** _____ / **C** _____ / **F** _____ (Location)
m tube is missing, x unknown / not visible, + or - Patency test

Source: © 2021 The Authors. Acta Obstetrica et Gynecologica Scandinavica published by John Wiley & Sons Ltd on behalf of Nordic Federation of Societies of Obstetrics and Gynecology (NFOG).

APPENDIX 3: Endometriosis Fertility Index (EFI) Surgery Form

**ENDOMETRIOSIS FERTILITY INDEX (EFI)
SURGERY FORM**

LEAST FUNCTION (LF) SCORE AT CONCLUSION OF SURGERY

Score	Description	Left	Right
4	= Normal		
3	= Mild Dysfunction		
2	= Moderate Dysfunction		
1	= Severe Dysfunction		
0	= Absent or Nonfunctional		

Fallopian Tube	<input type="text"/>	<input type="text"/>
Fimbria	<input type="text"/>	<input type="text"/>
Ovary	<input type="text"/>	<input type="text"/>

To calculate the LF score, add together the lowest score for the left side and the lowest score for the right side. If an ovary is absent on one side, the LF score is obtained by doubling the lowest score on the side with the ovary.

Lowest Score	<input type="text"/>	+	<input type="text"/>	=	<input type="text"/>
	Left		Right		LF Score

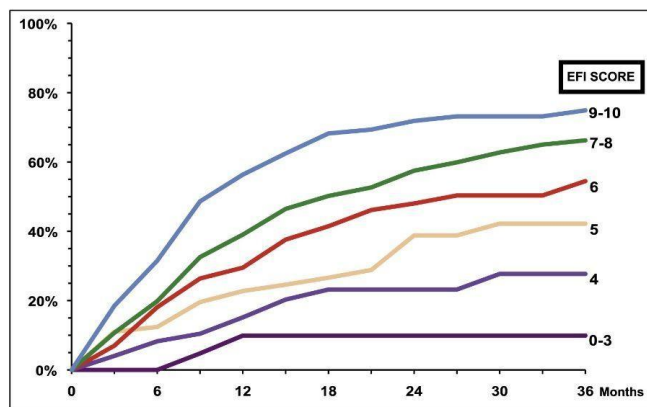
ENDOMETRIOSIS FERTILITY INDEX (EFI)

Historical Factors			Surgical Factors		
Factor	Description	Points	Factor	Description	Points
Age	If age is ≤ 35 years	2	LF Score	If LF Score = 7 to 8 (high score)	3
	If age is 36 to 39 years	1		If LF Score = 4 to 6 (moderate score)	2
	If age is ≥ 40 years	0		If LF Score = 1 to 3 (low score)	0
Years Infertile	If years infertile is ≤ 3	2	AFS Endometriosis Score	If AFS Endometriosis Lesion Score is < 16	1
	If years infertile is > 3	0		If AFS Endometriosis Lesion Score is ≥ 16	0
Prior Pregnancy	If there is a history of a prior pregnancy	1	AFS Total Score	If AFS total score is < 71	1
	If there is no history of prior pregnancy	0		If AFS total score is ≥ 71	0
Total Historical Factors			Total Surgical Factors		

EFI = TOTAL HISTORICAL FACTORS + TOTAL SURGICAL FACTORS:

<input type="text"/>	+	<input type="text"/>	=	<input type="text"/>
Historical		Surgical		EFI Score

ESTIMATED PERCENT PREGNANT BY EFI SCORE



Source: © 2010 American Society for Reproductive Medicine. Published by Elsevier Inc.

APPENDIX 4: Pictorial Guide to Imaging in Endometriosis

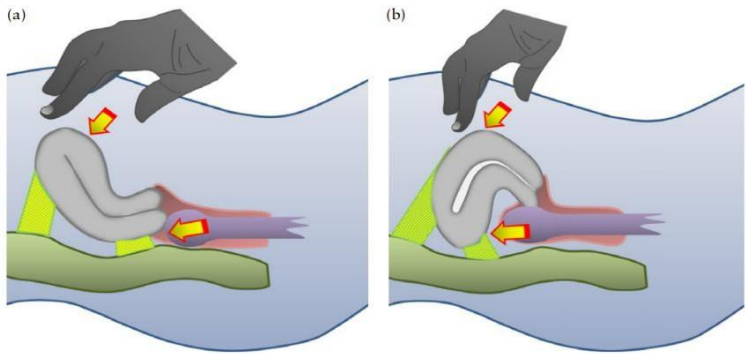
ULTRASOUND EXAMINATION FOR ENDOMETRIOSIS

- Begin with a **systematic overview of the entire pelvis**
- Assess the **uterus and ovaries** for features of endometriosis, adenomyosis, and ovarian endometriotic cysts.
- Perform **dynamic assessment** for:
 - Site-specific tenderness
 - Ovarian mobility
 - Sliding sign between the uterus and adjacent structures
- Evaluate for **deep endometriosis**, in relation to uterus and surrounding **compartments**.
 - **Anterior compartment:** Urinary bladder, uterovesical region, ureters
 - **Posterior compartment:** USLs, posterior vaginal fornix, anterior rectum, anterior rectosigmoid junction and sigmoid colon
- Identify **adhesions** associated with endometriosis, **distinct from the endometrial lesions** themselves.

Steps in Ultrasound Evaluation of Endometriosis

Adopted from Systematic approach to sonographic evaluation of the pelvis in women with suspected endometriosis, including terms, definitions and measurements: a consensus opinion from the International Deep Endometriosis Analysis (IDEA) group. *Ultrasound Obstet Gynecol.* 2016;48(3):318-332

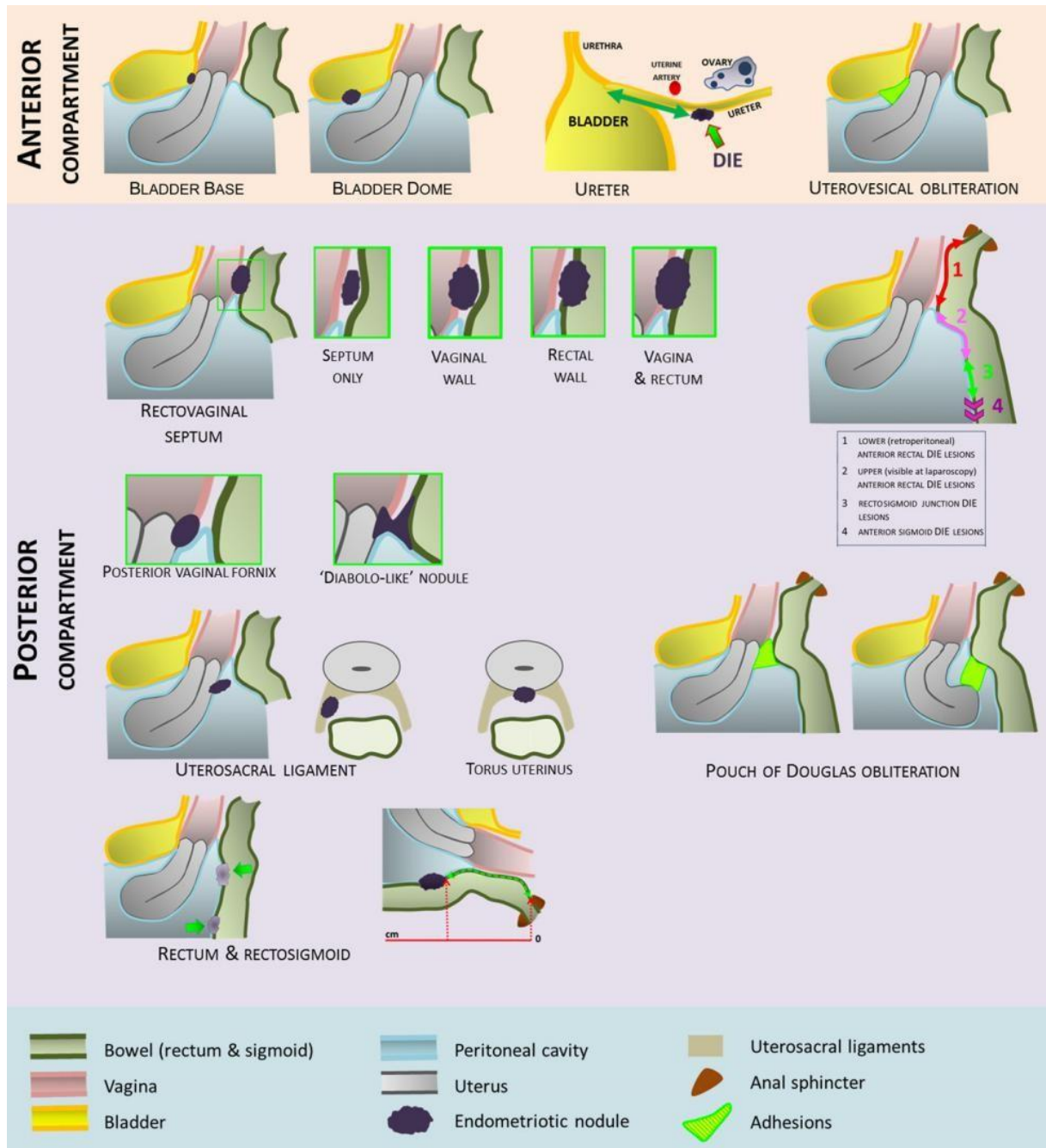
Step	Sonographic Assessment	Key Findings
Step 1	<p>Evaluate uterus and adnexa</p> <p>Maps extent of disease</p> <p>Helps differentiate benign vs suspicious ovarian lesions</p> <p>“Kissing ovaries” suggest severe pelvic adhesions and increased likelihood of bowel and tubal involvement</p> <p>Pregnancy-related decidualization of endometriomas may mimic malignancy</p>	<ul style="list-style-type: none"> • Assess uterine mobility: normal, reduced, or fixed (“question mark sign”) • Look for adenomyosis features Morphological Uterus Sonographic Assessment (MUSA) classification. • Identify endometriomas: size (3 orthogonal planes), number, morphology • Describe lesions using International Ovarian Tumor Analysis (IOTA) terminology • Recognize features of atypical endometrioma (unilocular-solid, ground glass echogenicity, papillary projection, low color score, no internal flow) • Look for “kissing ovaries” sign
Step 2	<p>Assess soft markers and adhesions</p> <p>Soft markers increase likelihood of superficial endometriosis and adhesions</p> <p>Tubal distortion or occlusion may indicate associated tubal disease and infertility risk</p>	<ul style="list-style-type: none"> • Check for site-specific tenderness (SST) • Apply pressure between the uterus and ovaries to assess ovarian mobility and fixation (determine fixation medially, laterally, or to uterosacral ligaments) • Evaluate whether uterus or ovaries are adherent to surrounding structures by palpation (with the probe and/or with the free hand) • Identify adhesions to broad ligament, Pouch of Douglas, bladder, rectum and/or parietal peritoneum • Identify fine adhesive strands in pelvic fluid between the ovary and uterus or the Pouch of Douglas • Search for hydrosalpinx, hematosalpinx, and peritoneal cysts

<p>Step 3</p>	<p>Assess pouch of Douglas (POD) using the “sliding sign”</p> <p>Detects POD obliteration and deep adhesions as well as level of the obliteration</p> <p>Important predictor of severe posterior compartment disease and surgical complexity</p>	<ul style="list-style-type: none"> • Anteverted uterus: By applying gentle pressure against the cervix using the TVS probe, determine whether rectum glides freely over retrocervix and posterior vaginal wall (lower) and by balloting the uterus between a palpating hand and the TVS probe, assess sliding sign of the bowel over the posterior uterus/fundus (upper) • Retroverted uterus: By applying gentle pressure against the posterior upper uterine fundus with the TVS probe, assess whether rectum glides over posterior fundus (lower) and ballot the uterus between a palpating hand and the TVS probe to assess sliding sign of the sigmoid over anterior lower uterine segment (upper) • Positive sliding sign in all regions = POD not obliterated • Negative sliding sign in ≥ 1 region = POD obliterated
<div style="text-align: center;">  <p>Schematic drawings demonstrating how to elicit the 'sliding sign' in an anteverted uterus (a) and a retroverted uterus (b).</p> </div>		
<p>Step 4</p>	<p>Search for deep infiltrating endometriosis (DIE)</p> <p>Identifies DIE nodules and extent of anterior and posterior compartment involvement</p> <p>TVS is accurate for rectosigmoid DIE even without bowel preparation</p>	<ul style="list-style-type: none"> • Examine anterior compartment by placing transducer in the anterior vaginal fornix • Evaluate bladder wall; slight bladder filling may improve detection • Examine posterior compartment by placing transducer in the posterior fornix and while slowly withdrawing probe • Assess bowel, rectovaginal septum, uterosacral ligaments, and posterior vaginal fornix • Bowel preparation/enema may improve visualization but is not mandatory

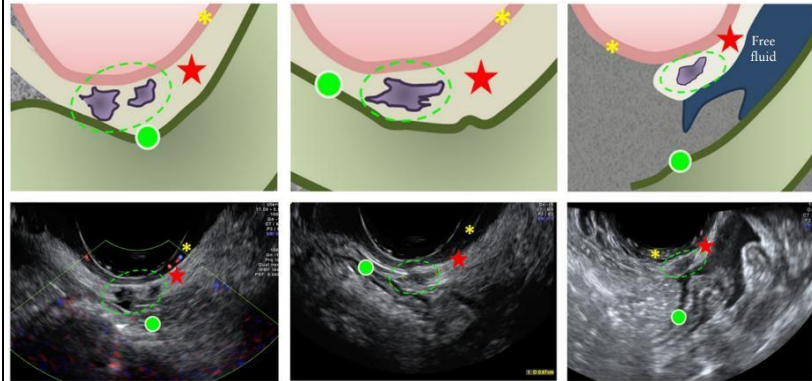
ULTRASOUND FINDINGS

Compartmental Evaluation for Deep Endometriosis

Adopted from Systematic approach to sonographic evaluation of the pelvis in women with suspected endometriosis, including terms, definitions and measurements: a consensus opinion from the International Deep Endometriosis Analysis (IDEA) group. *Ultrasound Obstet Gynecol.* 2016;48(3):318-332



Schematic drawings giving overview of anterior and posterior compartmental locations of deep infiltrating endometriosis.

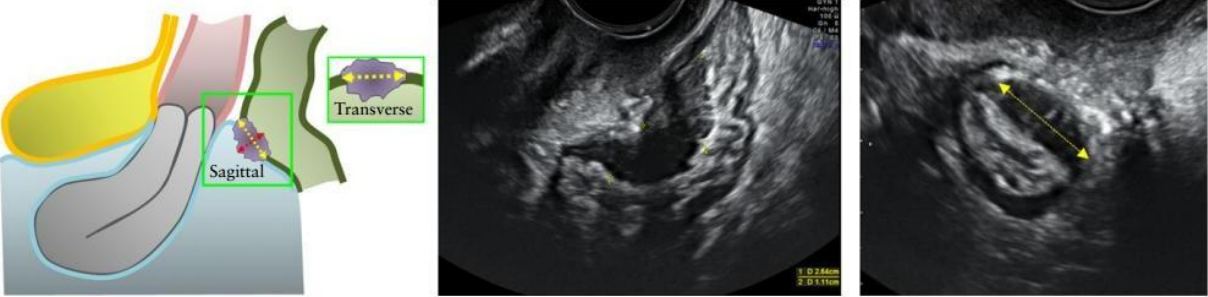
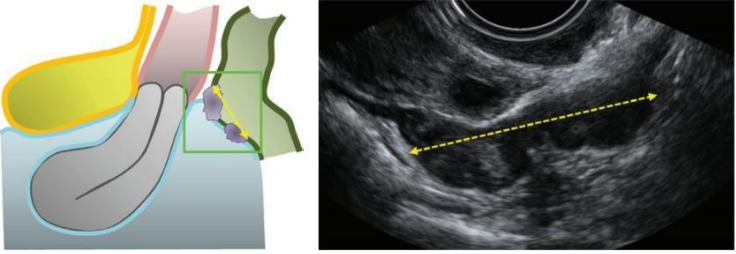
Compartment / Structure	Key Ultrasound Findings and Methods	
Anterior Compartment: <i>Includes bladder, uterovesical region, and ureters</i>		
Urinary Bladder	DIE appears as hypoechoic linear or spherical lesions involving muscularis or submucosa	<ul style="list-style-type: none"> • Bladder best assessed partially filled. • Four zones: (i) trigone, (ii) bladder base, (iii) bladder dome, (iv) extra-abdominal bladder. • Bladder base is the commonest site. • Lesions involving only serosa = superficial disease. • Measure lesions in 3 orthogonal planes.
Uterovesical Region	Evaluated using the sliding sign	<ul style="list-style-type: none"> • Placement of transvaginal probe in the anterior fornix and ballotment of uterus. • Positive sliding sign = non-obliterated uterovesical space. • Negative sliding sign = obliterated uterovesical space, • Adhesions related to prior Cesarean section may also cause negative sliding sign.
Ureters	Ureters appear as tubular hypoechoic structures with hyperechoic mantle extending from lateral aspect of bladder towards the common iliac vessels.	<ul style="list-style-type: none"> • Examine distal ureters routinely by identifying the urethra in sagittal plane and moving probe towards the lateral pelvic wall, identifying the intravesical ureter, following its course to where it leaves the bladder, then to the pelvic side wall and up the level of bifurcation of common iliac vessels. • Observation of peristalsis confirms ureteric patency. • Look for dilatation, strictures, extrinsic compression, or intrinsic infiltration. • Measure distance from ureteric orifice to stricture. • In cases with suspicion of DIE, assess kidneys for hydronephrosis. Hydronephrosis requires urgent referral/stenting.
Posterior Compartment: <i>Includes Uterosacral ligaments (USLs), posterior vaginal fornix, rectum, rectosigmoid junction, sigmoid colon. Lesions appear as hypoechoic wall thickening or solid nodules with smooth/irregular margins</i>		
Rectovaginal Septum (RVS)	DIE nodules in rectovaginal space below lower border of the posterior cervical lip (under the peritoneum)	<ul style="list-style-type: none"> • Isolated RVS disease is rare. Usually extension from vagina and/or rectum. • Sonovaginography improves detection. • Measure lesion size in three orthogonal planes and measure the distance between lower margin of lesion and anal verge. • Low RVS lesions carry higher surgical complication risk.
	 <p data-bbox="1219 1528 1450 1808">Schematic drawings and ultrasound images demonstrating isolated deep infiltrating endometriosis in the rectovaginal septum (RVS, ★). The green ellipses encircle the endometriotic nodules in the RVS. Bowel wall, ●; Vaginal wall, ★.</p>	

<p>Vaginal Wall</p>	<p>Seen as a thickening or discrete nodules in posterior/lateral vaginal fornix</p>	<ul style="list-style-type: none"> • Nodule in rectovaginal space below the lower margin of the Pouch of Douglas and above the lower border of posterior cervical lip (under the peritoneum). • Lesions may be homogeneous or heterogeneous and with or without cystic areas. • Measure lesion in three orthogonal planes.
<p>Rectovaginal (“Diabolo”) Nodules</p>	<p>Hourglass- or diabolo-shaped lesions extending from posterior vaginal fornix into anterior rectal wall</p>	<ul style="list-style-type: none"> • The part of the lesion situated in anterior rectal wall is the same size as the part situated in posterior vaginal fornix, connected by a narrow bridge of tissue. • Usually large (average 3cm) lesions and located below POD peritoneum.
<p>Uterosacral Ligaments (USLs)</p>	<p>Hypoechoic thickening with regular or irregular margins within peritoneal fat surrounding the USLs</p>	<ul style="list-style-type: none"> • Best assessed by placing probe from posterior fornix in midsagittal plane, then sweeping inferolaterally towards the cervix • Lesions may extend into adjacent structures. • Torus uterinus involvement appears as a central retro-cervical thickening. • Measure lesions in three orthogonal planes.
<p>Rectum / Rectosigmoid junction / Sigmoid</p>	<p>Thickening of the muscularis propria or hypoechoic nodules ± hyperechoic foci</p>	<ul style="list-style-type: none"> • Histologically defined as presence of endometrial glands and stroma in the bowel wall, reaching at least the muscularis propria • May be isolated or multifocal (multiple lesions affecting the same segment), and/or multicentric (multiple lesions affecting several bowel segments). • Typical signs include “comet sign”, “Indian headdress”, or “moose antler” appearance. • Measure lesion size (use three orthogonal dimensions to measure rectal and rectosigmoid DIE) and measure the distance from anal verge.
<p>Rectum / Rectosigmoid junction / Sigmoid</p>		<p>Schematic drawings and corresponding ultrasound images of bowel deep infiltrating endometriosis (DIE).</p> <p>(a) DIE nodule with a regular outline (absence of 'spikes').</p> <p>(b) DIE nodule with progressive narrowing, like a 'tail', also known as 'comet' sign.</p> <p>(c) DIE nodule with prominent spikes towards the bowel lumen, also known as 'Indian headdress' or 'moose antler' sign.</p> <p>(d) DIE nodule with both prominent spikes towards the bowel lumen (Indian headdress/moose antler sign) and progressive narrowing like a tail (comet sign).</p> <p>(e) DIE nodule with both prominent spikes towards the bowel lumen (Indian headdress/moose antler sign) and extrinsic retraction (and visible mucosal folds) (known as 'pulling sleeve' sign). The sliding sign is expected to be negative.</p> <p>(f) DIE nodule and extrinsic retraction (pulling sleeve sign). The sliding sign is expected to be negative.</p> <p>Ultrasound image shows bowel adherent to the ovary; the hypoechoic area between the bowel loops and the ovary to which the bowel is adherent correspond to linear endometriotic changes (containing endometriotic glands and stroma) not involving the muscularis of the bowel wall but located between the bowel and the ovary.</p>

Bowel DIE Description	Classified according to anatomical level	<ul style="list-style-type: none"> • Lower anterior rectum (below USL insertion on cervix) - <i>retroperitoneal</i> • Upper anterior rectum (above USL insertion on cervix) – <i>visible at laparoscopy</i> • Rectosigmoid junction (at the level of uterine fundus) • Sigmoid colon (above level of uterine fundus)
	<p>Schematic drawing demonstrating distinction at ultrasound between segments of the rectum and sigmoid colon for specifying location of deep infiltrating endometriotic lesions: lower (or retroperitoneal) anterior rectum (1); upper (visible at laparoscopy) anterior rectum (2); rectosigmoid junction (3); and anterior sigmoid (4).</p>	
Pouch of Douglas (POD)	Evaluated using sliding sign	<ul style="list-style-type: none"> • Partial obliteration = one side (right/left) negative. • Complete obliteration = both sides negative. • Level of obliteration can also be specified <p>In an anteverted uterus</p> <ul style="list-style-type: none"> - Retro-cervical level (lower third of uterus) - Mid-posterior level (middle third) - Posterior uterine fundus (upper third) <p>In a retroverted uterus</p> <ul style="list-style-type: none"> - Posterior uterine fundus - Mid-anterior uterus - Lower anterior uterine wall
Multifocal bowel disease	Multifocal bowel disease common	<ul style="list-style-type: none"> • MRI or CT colonography useful for multifocal/multicentric bowel disease. • Renal assessment mandatory in suspected ureteric disease.

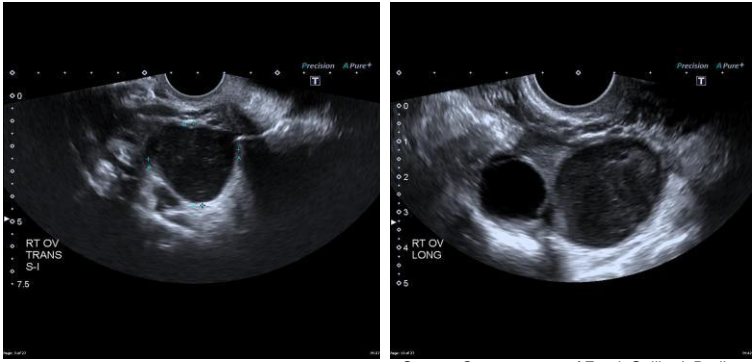
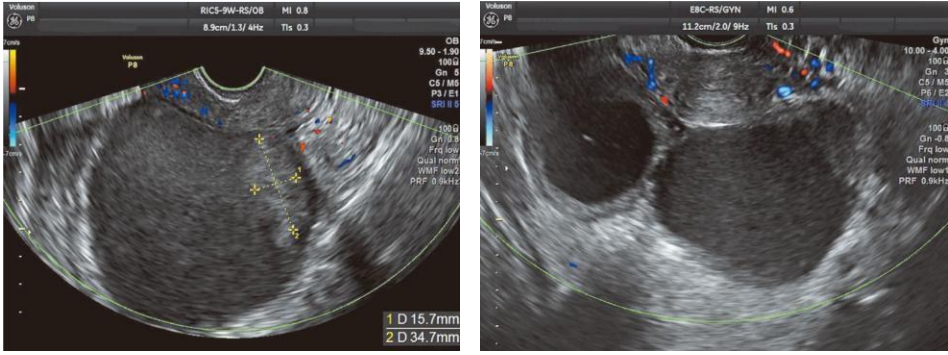
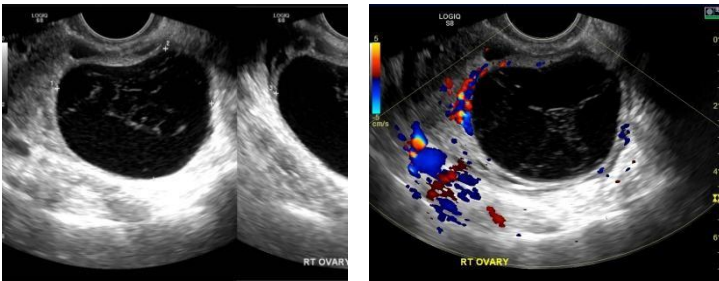
Adopted from Systematic approach to sonographic evaluation of the pelvis in women with suspected endometriosis, including terms, definitions and measurements: a consensus opinion from the International Deep Endometriosis Analysis (IDEA) group. *Ultrasound Obstet Gynecol.* 2016;48(3):318-332

Measurement of Lesions

Lesion Type	Measurement Method	
General Measurement of Endometriomas and DIE Lesions	Measure in 3 orthogonal planes	Record: length (mid-sagittal), thickness (anteroposterior), and transverse diameter. Applies to bladder, RVS, vagina, USLs, anterior rectum, and rectosigmoid lesions.
 <p>Schematic drawing and ultrasound images demonstrating measurement of a nodule of deep infiltrating endometriosis in the bowel wall. Three orthogonal measurements should be taken, i.e. mid-sagittal, anteroposterior and transverse.</p>		
Bladder DIE	Measure lesion in 3 planes	Assess dimensions systematically to define extent of muscular involvement.
Rectovaginal Septum (RVS) DIE	Measure lesion in 3 planes	Also measure distance from lesion to anal verge.
Vaginal DIE	Measure lesion in 3 planes	Includes posterior and lateral vaginal fornix lesions.
Uterosacral Ligament (USL) DIE	Measure lesion in 3 planes	Thickness may also be assessed at cervical insertion if clearly visualized.
Rectal / Rectosigmoid DIE	Measure lesion in 3 planes	Also measure distance from anal verge to lower margin of lesion.
Ureteric Endometriosis	Measure distance between distal ureteric orifice and ureteric stricture	Stricture may result from extrinsic compression or intrinsic infiltration. Measurement performed along longitudinal course of ureter.
Multifocal Bowel DIE	Measure total mid-sagittal length of bowel segment involved	Measure from most caudal to most cephalic lesion.
 <p>In cases of multifocal lesions of deep infiltrating endometriosis in the bowel, the total length of the bowel segment involved (from caudal to cephalic aspect) should be measured, as shown in this schematic drawing and ultrasound image.</p>		
Rectosigmoid DIE Retraction	Be cautious interpreting lesion dimensions	Retraction may overestimate lesion thickness and underestimate lesion length ("mushroom cap" sign).
Distance from Anal Verge to Lesion	Measured using transrectal sonography or approximated on TVS	Important for bowel and RVS lesions. In multifocal disease, measure distance to the most caudal lesion.
Transrectal Sonography Technique	Probe inserted to lesion level and external measurement taken after withdrawal	Provides more accurate lesion-to-anal verge distance assessment.
Overall Mapping of DIE	Combine anterior and posterior compartment assessment	Enables comprehensive localization and surgical planning.

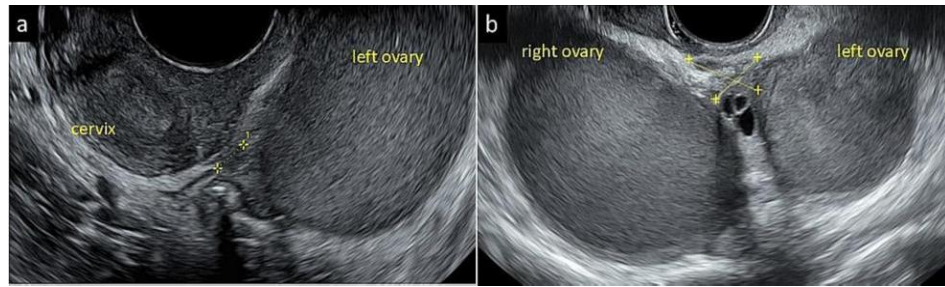
Adopted from Systematic approach to sonographic evaluation of the pelvis in women with suspected endometriosis, including terms, definitions and measurements: a consensus opinion from the International Deep Endometriosis Analysis (IDEA) group. *Ultrasound Obstet Gynecol.* 2016;48(3):318-332

Evaluation of Ovarian Endometriomas

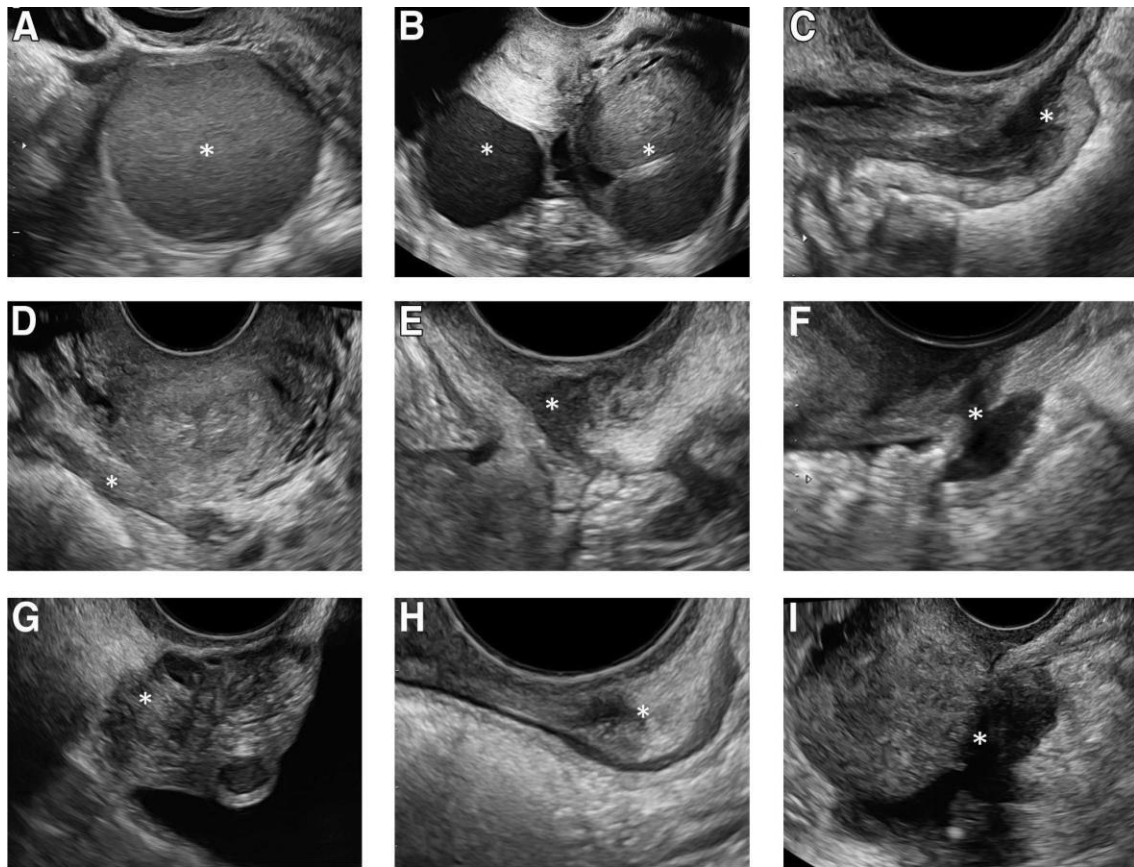
Features	Findings
Shape and site	Ovarian endometriotic cysts present as nearly circular or elliptical, unilocular or multilocular cysts that adhere to the uterus and are often located in the posterior aspect of the uterus or the rectovaginal pouch.
Cyst wall	Often thickened (appearance not neoplastic, absence of papillary projections)
Internal echoes	Accumulated and free-floating blood: uniform diffuse echoes or low intensity punctate spotty echoes (ground-glass appearance)
	 <p>Source: Case courtesy of Frank Gaillard, Radiopaedia.org, rID: 23580</p>
Hyperechoic regions and solid echoes	Blood clots and fibrin clots / Hemosiderin deposits; demonstrate fluidity due to postural changes and shows rippling motion when cysts are vibrated from the abdominal wall manually or with a vaginal probe
Blood flow	Absence of blood flow within cyst/ within fibrin clots
	 <p>Source: Clinical practice guidelines for endometriosis in Japan (The 3rd edition), J. Obstet. Gynaecol. Res. Vol. 48, No. 12: 2993–3044, December 2022, doi:10.1111/jog.15416</p>
Septations / Locules	Often unilocular, occasional smooth, thin septa with few locules (fish net appearance of haemorrhagic ovarian cysts). Consider ovarian cancer if septa are thick, irregular, with dendritic or papillary projections
	 <p>Source: Case Alexandra Stanislavsky, Radiopaedia.org, rID: 15903</p> <p>courtesy of</p>

Kissing endometriotic cysts

Bilateral ovarian endometriotic cysts, usually localised in the rectovaginal pouch; cysts adherent to the ovarian tissue and to each other.



Source: European Journal of Obstetrics & Gynecology and Reproductive Biology 313 (2025) 114639, doi.org/10.1016/j.ejogrb.2025.114639, Severe dysmenorrhea in adolescents need non-invasive ultrasound evaluation to early detect endometriosis/adenomyosis

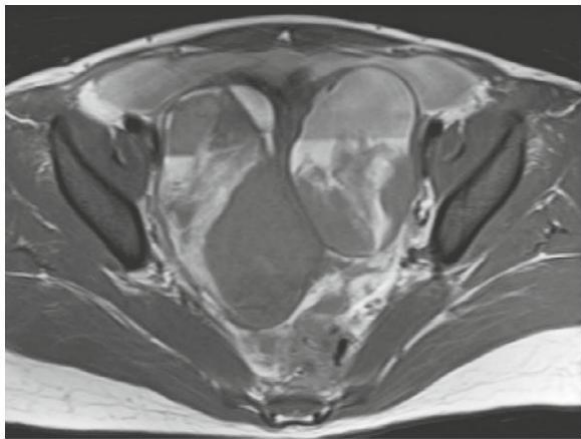


Ultrasound images demonstrating various endometriotic lesions at transvaginal sonography examination. The asterisk * marks the lesion: **(A)** Endometrioma, **(B)** bilateral endometriomas with kissing ovaries in transverse plane, **(C)** hypoechoic lesion in muscle layer of the anterior bowel wall, **(D)** endometriotic lesion in the right uterosacral ligament in a transverse plane, **(E)** endometriotic lesion in the vaginal wall, **(F)** "diabolo-like" nodule, **(G)** endometriotic lesion in the bladder, **(H)** endometriotic lesion in the rectovaginal septum, **(I)** obliteration of the pouch of Douglas with endometriotic nodule in the bowel adherent to the uterus.

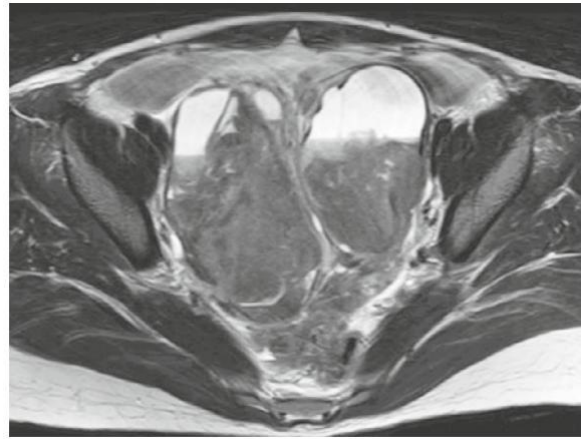Source: Prevalence of endometrioma and deep infiltrating endometriosis at transvaginal ultrasound examination of subfertile women undergoing assisted reproductive treatment, doi.org/10.1016/j.fertnstert.2022.07.024, Fertility and Sterility® Vol. 118, No. 5, November 2022 0015-0282. Image by Alson. Endometriosis in women with subfertility. Fertil Steril 2022.

MAGNETIC RESONANCE IMAGING

- MRI “can specifically diagnose the blood flow based on signals.” Hematomas present characteristic signals from bleeding that change over time, facilitating the deduction of timing and composition.
- Pelvic MRI findings. In the early stage of a hemorrhage, ovarian endometriotic cysts contain different stages of clotting and therefore present with varying MRI signals.
- MRI is currently the gold standard imaging modality in patients with deep infiltrating endometriosis.

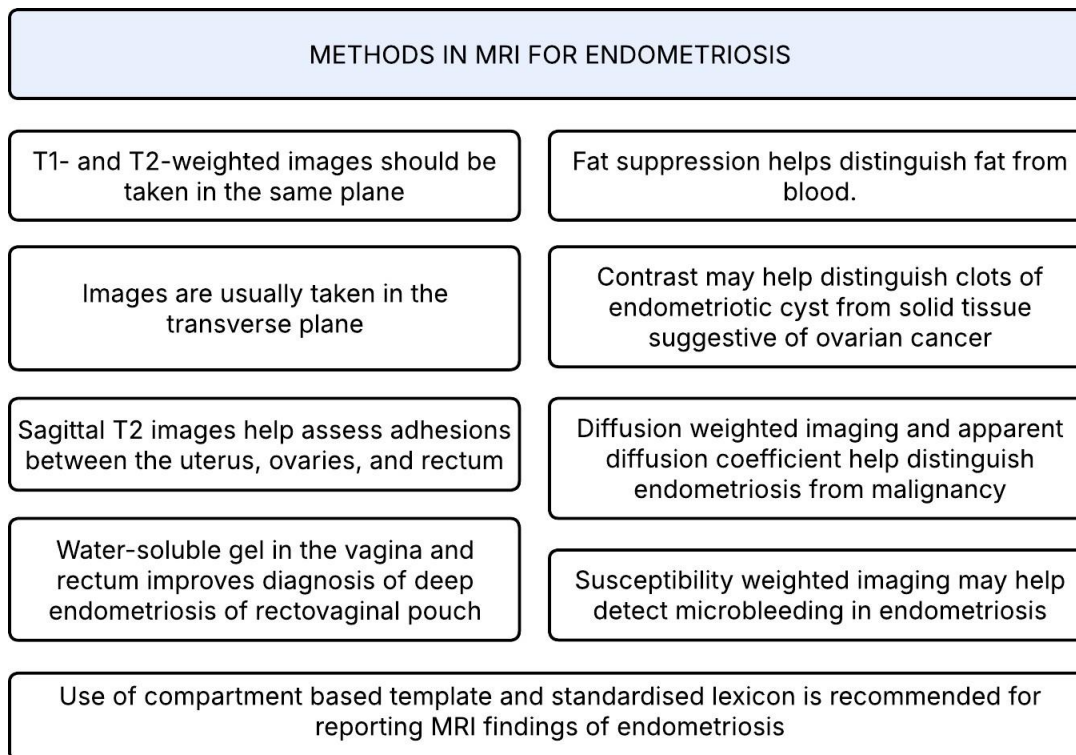


T1-weighted image



T2-weighted image

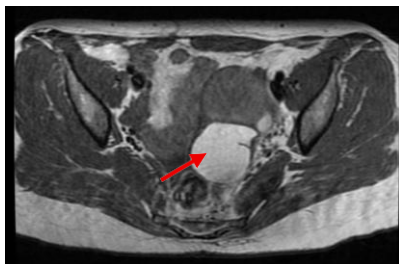
Source: Clinical practice guidelines for endometriosis in Japan (The 3rd edition), J. Obstet. Gynaecol. Res. Vol. 48, No. 12: 2993–3044, December 2022, doi:10.1111/jog.15416



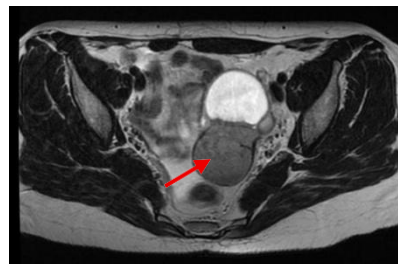
MRI FINDINGS

Features of ovarian endometriomas

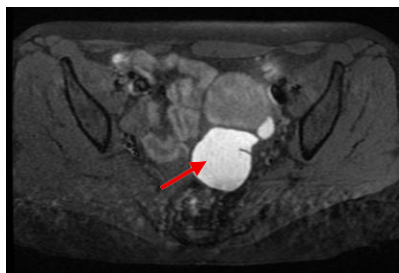
General	<ul style="list-style-type: none"> • Typically multifocal and often bilateral • May be unilocular or multilocular cysts • Contain chronic blood products of varying ages due to repeated cyclical bleeding • Often persist over time and may coexist with other features of endometriosis (e.g., deep endometriosis, hematosalpinx) • MRI signal characteristics reflect different stages of hemorrhage and clot evolution
T1-weighted imaging (T1WI)	<ul style="list-style-type: none"> • Homogeneous, markedly hyperintense signal similar to that of subcutaneous fat • Signal persists on fat-suppressed sequences (distinguishes hemorrhagic from fat-content) • Multiple cysts with non-suppressed high T1 signal support blood-filled cysts
T2-weighted imaging (T2WI)	<ul style="list-style-type: none"> • T2 shading sign: heterogeneous or diffuse low signal intensity due to chronic, viscous blood • T2 hypointense wall from fibrosis and hemosiderin deposition (high specificity) • T2 dark spots: focal markedly hypointense areas representing retracted blood clots (high specificity)
Diffusion-weighted imaging (DWI)	<ul style="list-style-type: none"> • May show diffusion restriction due to thick endometriotic fluid • Not indicative of malignancy in the absence of solid enhancing components
Contrast-enhanced imaging (CE-MRI)	<ul style="list-style-type: none"> • Smooth wall enhancement may be present • Subtraction images are essential to assess for enhancing solid tissue • Presence of enhancing solid components raises concern for malignant transformation



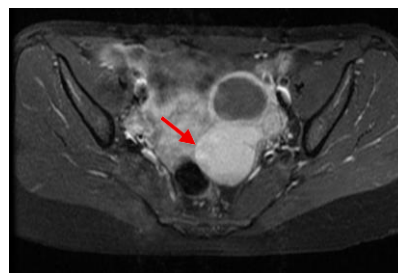
T1-weighted image



T2-weighted image



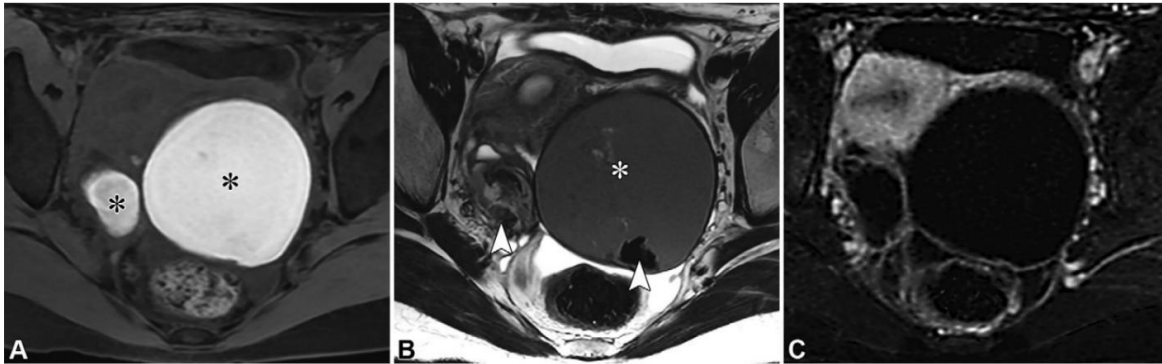
T1-weighted image with fat saturation



T1-weighted with post contrast enhancement

Left ovarian multi-locular cyst showing cystic and hemorrhagic components. The hemorrhagic component (red arrows) elicits high signal at T1WI and low signal at T2WI. The high signal at fat saturation sequences excludes fat nature and suggests hemorrhagic components, and there is mild marginal post contrast enhancement.

Source: Case courtesy of The Radswiki, Radiopaedia.org, rID: 11397



Bilateral endometriomas in a 20-year-old female patient with dysmenorrhea. (A, B) Axial fat-saturated T1-weighted (A) and T2-weighted (B) images show classic features of endometriomas, such as bilateral T1-hyperintense lesions (* in A) with T2 shading (* in B), T2-hypointense walls, and intralesional T2-dark spots (arrowheads in B), all indicative of chronic repetitive hemorrhage. (C) Contrast-enhanced fat-saturated T1-weighted image with subtraction confirms the absence of enhancing solid tissue.

Source: Reference Handbook of Gynecologic Pelvic MRI, Alexander and Nougaret et. al., RadioGraphics 2026; 46(2):e250029; <https://doi.org/10.1148/rg.250029>

Differential Diagnoses for Endometriomas

DIFFERENTIAL DIAGNOSES FOR ENDOMETRIOMAS	FEATURES
Ovarian mature teratoma	Fat saturation distinguishes fat from blood; chemical shift artifact and morphology are also helpful
Corpus luteum	High signal hematocrit effect at the cyst base suggests functional intracystic haemorrhage
Ovarian tumoral haemorrhage	Mixed blood and fluid usually show lower signal intensity than pure blood or fat
Ovarian carcinoma	Solid components raise concern; clots do not enhance, while mural nodules enhance strongly; DWI is helpful
Hydrosalpinx	Typically appears as a tubular structure with variable signal

Features of Deep Infiltrating Endometriosis and Adhesive Changes

Deep endometriotic lesions result from fibrosis with variable areas of hemorrhage.

Standardized MRI compartment-based structured reporting is recommended to enable consistent accuracy and help select the best therapeutic approach and patient information.

Features of Endometriotic Lesions	<ul style="list-style-type: none"> • Lesions reflect fibrosis with variable hemorrhagic components, explaining: <ul style="list-style-type: none"> ○ Predominantly low T2 signal (fibrosis) ○ Scattered high T1/T2 foci (active glands/bleeding)
Adhesive changes	<ul style="list-style-type: none"> • Only pronounced adhesions are reliably detected on MRI • Associated with restricted organ mobility and architectural distortion • Suspicious features include: <ul style="list-style-type: none"> ○ “Kissing ovaries” (bilateral ovaries in contact, typically posterior to uterus) ○ Ovary adherent to uterus or pelvic wall over a broad surface ○ Bowel angulation / tethering with beak-like distortion toward uterus or ovary ○ Tethering of adjacent structures ○ Uterine retroflexion or lateral deviation ○ External adenomyosis (outside-in pattern, sparing junctional zone)
Deep endometriosis	<ul style="list-style-type: none"> • Most severe form, typically multifocal and predominantly pelvic • Common sites to assess: <ul style="list-style-type: none"> ○ Uterosacral ligaments / torus uterinus ○ Rectosigmoid colon ○ Posterior uterine surface ○ Posterior vaginal fornix ○ Round ligaments ○ Urinary bladder ○ Ovarian surface • Frequently coexists with: <ul style="list-style-type: none"> ○ Endometriomas ○ Hematosalpinx

MRI signal characteristics of deep endometriosis

T1-weighted imaging (T1WI)	<ul style="list-style-type: none"> • Lesions are iso- to hypointense (fibrotic tissue) • May contain T1 hyperintense foci (hemorrhagic ectopic glands) persisting after fat suppression
T2-weighted imaging (T2WI)	<ul style="list-style-type: none"> • T2 hypointense (fibrotic) nodules or thickening (stellate or smooth) • T2 hyperintense foci may be present (active glands)
Diffusion-weighted imaging (DWI)	<ul style="list-style-type: none"> • Typically hypointense on DWI and ADC (fibrotic tissue) • Areas of hemorrhage may alter signal
Contrast-enhanced imaging (CE-MRI)	<ul style="list-style-type: none"> • Mild, slow progressive enhancement (fibrosis) • More avid enhancement may indicate inflammation

Compartment Based Structured Reporting Template for Deep Endometriosis

Adopted from Deep pelvic infiltrating endometriosis: MRI consensus lexicon and compartment-based approach from the ENDOVALIRM group. *Diagn Interv Imaging.* 2023;104(3):95-112

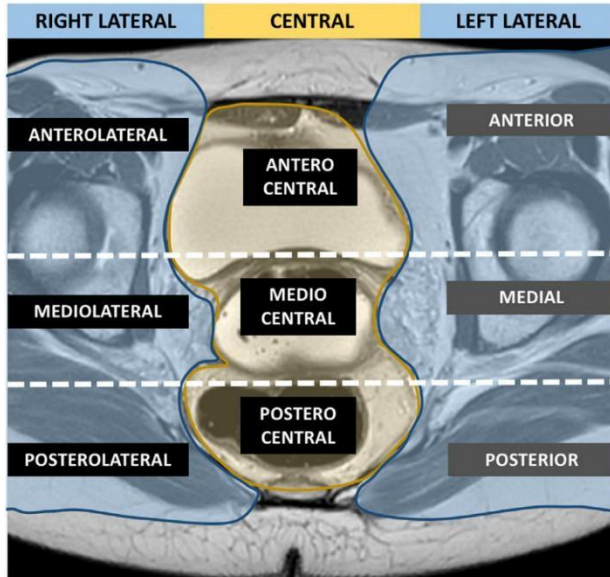


Diagram illustrates the delineation of the nine pelvic compartments.

T2-weighted MR image of the pelvis in the axial plane at the level of USL (subperitoneal level).

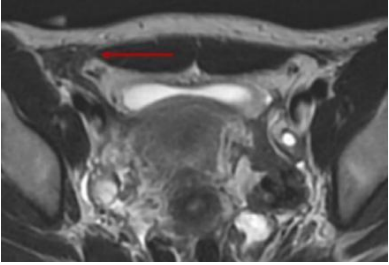
The pelvis is divided into nine compartments based on anatomical description.

Two horizontal lines divide the pelvis in anterior, median and posterior parts with an anterior line passing at the anterior to the cervix or vagina and a posterior line passing anterior to the rectum. Two vertical lines divide the pelvis in a central and two lateral parts, each line passing from back to front by the uterosacral ligaments and the underlying fascia recti, the lateral border of the uterine cervix or vagina, and the lateral wall of the bladder.

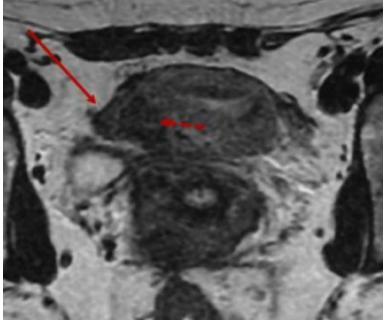
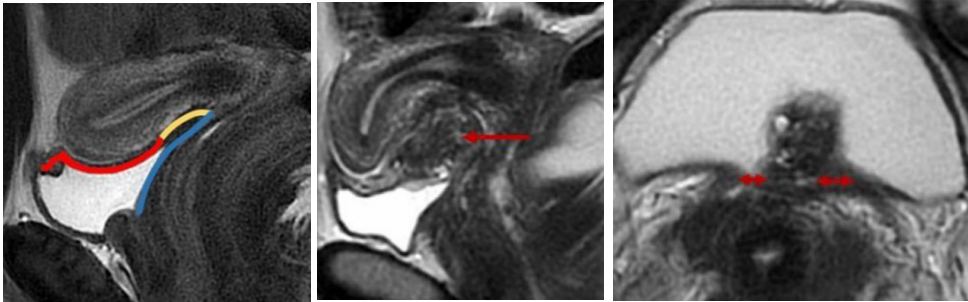
Individual Structures Assigned to Specific Compartment

<p style="text-align: center;">Anterolateral</p> <p>Distal round ligament</p>	<p style="text-align: center;">Anterocentral</p> <p>Proximal round ligament Bladder</p>	<p style="text-align: center;">Anterolateral</p> <p>Distal round ligament</p>
<p style="text-align: center;">Mediolateral</p> <p>Parametrium Ureter Uterine artery Pelvic wall : external iliac and/or obturator vessels</p>	<p style="text-align: center;">Mediocentral</p> <p>Torus and proximal uterosacral ligament(s) Posterior vaginal fornix Rectovaginal septum and anterior mesorectum Anterior and/or posterior external adenomyosis</p>	<p style="text-align: center;">Mediolateral</p> <p>Parametrium Ureter Uterine artery Pelvic wall : external iliac and/or obturator vessels</p>
<p style="text-align: center;">Posterolateral</p> <p>Distal uterosacral ligament Sacrorectogenital septum Pelvic wall - Sacral roots - Sciatic nerve - Internal iliac vessels</p>	<p style="text-align: center;">Postero-central</p> <p>Rectum and rectosigmoid junction</p>	<p style="text-align: center;">Posterolateral</p> <p>Distal uterosacral ligament Sacrorectogenital septum Pelvic wall - Sacral roots - Sciatic nerve - Internal iliac vessels</p>
<p style="text-align: center;">Extrapelvic</p> <p>Sigmoid colon Cecum- ileum- appendix Ureters at the level of common iliac artery Abdominal wall Inguinal regions</p>		

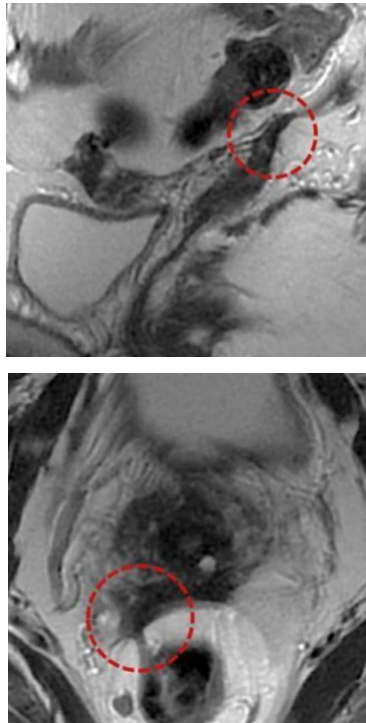
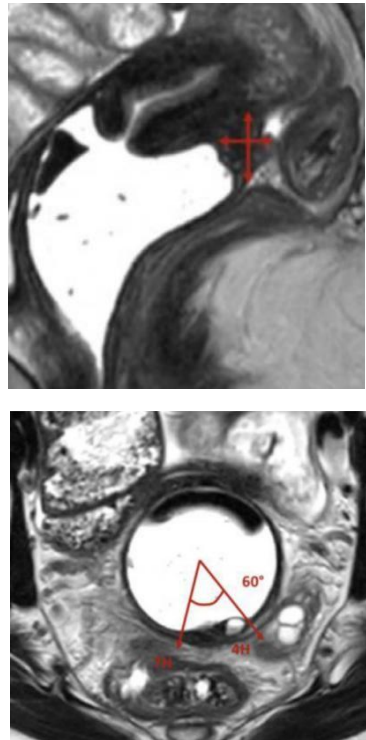
LEFT AND RIGHT ANTEROLATERAL COMPARTMENTS

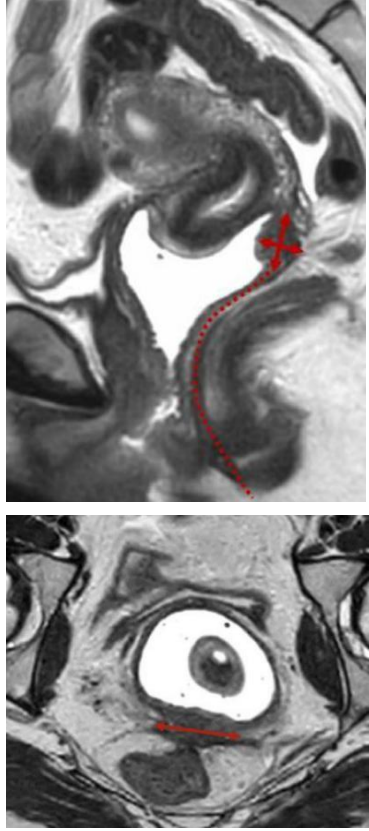
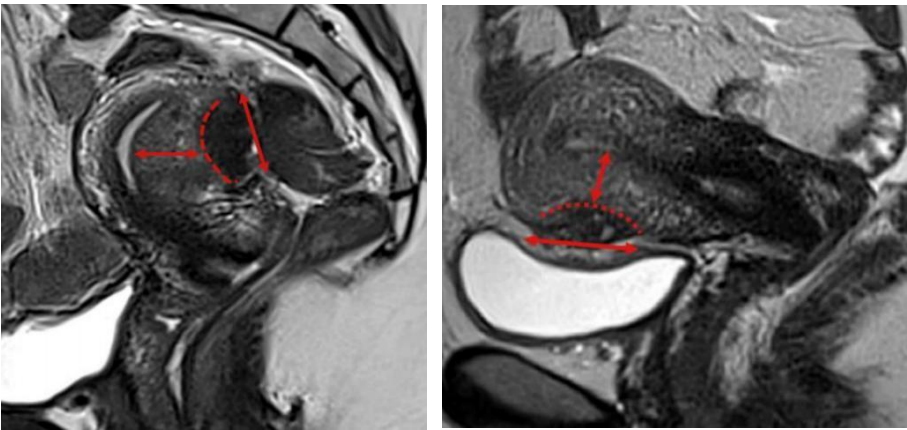
Anatomic Structure	Findings and Reporting
<p>Distal round ligament "Distal" correspond to the intrapelvic two thirds of round ligament, up to the deep orifice and/or into the inguinal canal.</p>	<p>Fibrotic nodular thickening (generally > 1cm) +/- hemorrhagic cystic area (arrow).</p> 

ANTEROCENTRAL COMPARTMENT

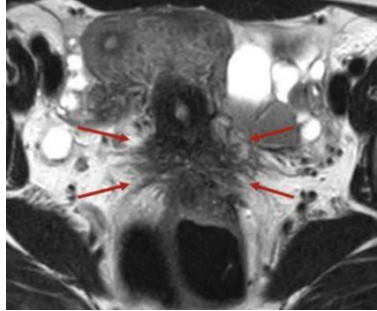
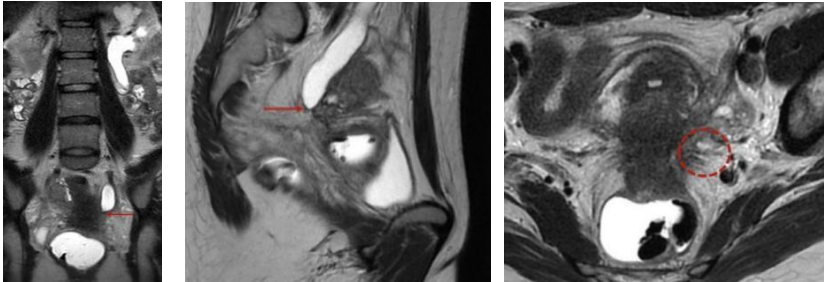
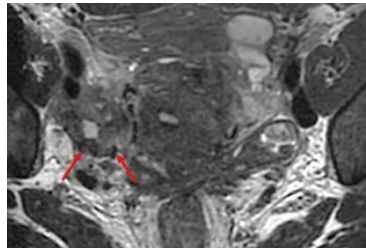
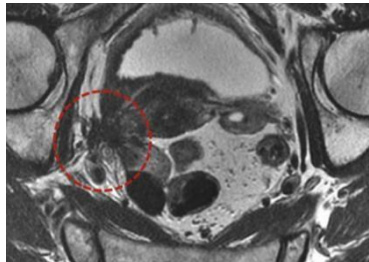
Anatomic Structure	Findings and Reporting
<p>Proximal round ligament "Proximal" correspond to intrapelvic third of round ligament.</p>	<p>Fibrotic nodular thickening (generally > 1cm) +/- hemorrhagic cystic area (arrow). Often associated with external adenomyosis (dashed arrow).</p> 
<p>Bladder</p>	<p>Nodule or mass involving the muscularis layer (arrow).</p> <p>Three different locations within the bladder wall:</p> <ul style="list-style-type: none"> - Anterior dome (red line). - Vesicouterine pouch (yellow line). - Bladder base (blue line). <p>Lateralization of the lesion: median, right-sided, or left-sided.</p> <p>Size in the three planes.</p> <p>Distance to ureteral orifice (double-headed arrows).</p>
	

MEDIOCENTRAL COMPARTMENT

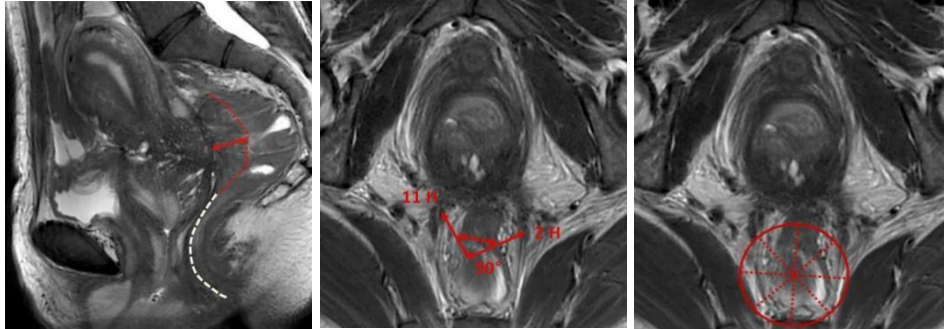
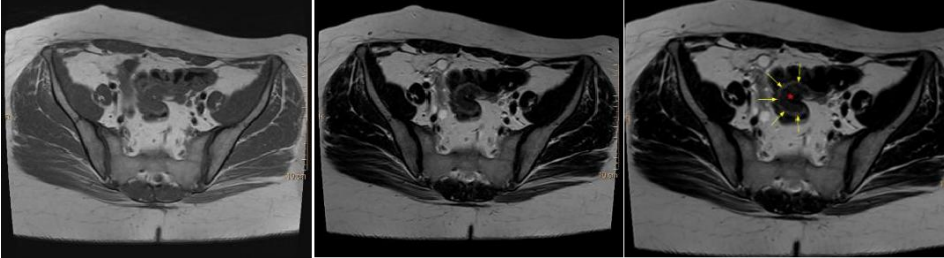
Anatomic Structure	Findings and Reporting	
<p>Torus and proximal uterosacral ligaments (USL) "Proximal" corresponds to USL \leq 2 cm from torus.</p>	<p><u>Positive diagnosis (dashed circle) if any of the following:</u> With or without hemorrhagic implant(s):</p> <ul style="list-style-type: none"> • Regular or irregular fibrotic thickening >5 mm • Nodular (defined as if nodule is present in two planes) • Retraction (spiculate defined as irregularity present in two planes, distortion of the shape, surrounding fat infiltration) <p>Presence of hemorrhagic implant(s), whatever the thickening</p> <p><u>Uncertain diagnosis when:</u> Irregular or pseudonodular (defined as present in only one plane) AND Fibrotic thickening between 3 and 5 mm.</p>	
<p>Posterior vaginal fornix</p>	<p>Nodule or thickening of the posterior vaginal wall. O'clock position. Length, thickness (double-headed arrows), transverse axis, and circumference by degree.</p>	

<p>Rectovaginal septum and anterior mesorectum</p>	<p>Nodule / mass located or extended between the vagina and the rectum, below the peritoneal pouch of Douglas reflection.</p> <p>Length, transverse axis, thickness (double-headed arrows) and distance to the anal verge (dashed line).</p>	
<p>External Adenomyosis (anterior or posterior)</p>	<p>Nodular fibrotic extrinsic infiltration of the myometrium with ill-defined borders (dashed lines) & hemorrhagic cystic area. Length of the lesion (double-headed arrows).</p> <p>Two levels of extension in depth: moderate (limited to the subserosal external myometrium) and severe (up to the junctional zone or more).</p> <p>Distance from the endometrium (double-headed arrows)</p>	

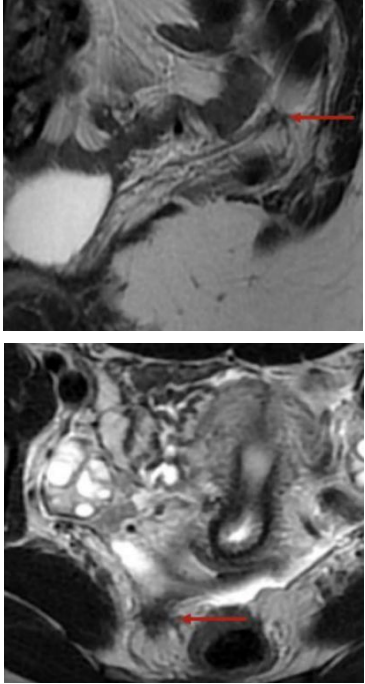
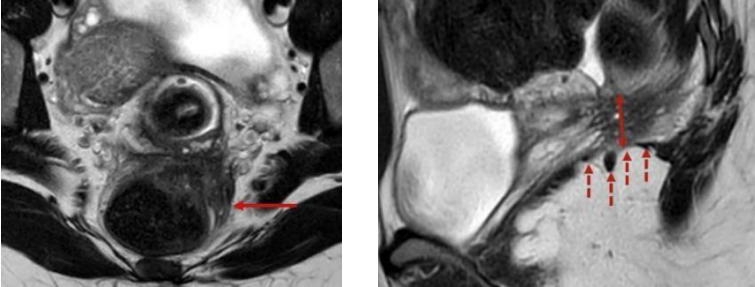
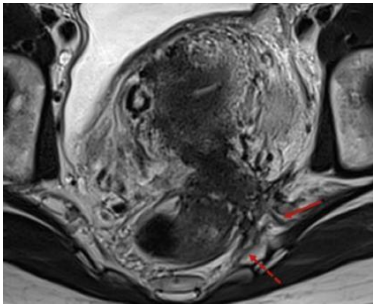
LEFT AND RIGHT MEDIOLATERAL COMPARTMENTS

Anatomic Structure	Findings and Reporting	
<p>Parametrium</p>	<p>Irregular and/or retractile fibrotic infiltration +/- hemorrhagic cystic area of vascular and adipocellular tissue of lateral or posterolateral cervical (arrows) or vaginal regions, between the anterior and posterior lines.</p> 	
<p>Ureter</p>	<p>Fibrotic infiltration with abolition of the peri ureteric cellular and fat signal (arrows) at the entry of the ureter in the parameter or more posteriorly at the level where it runs behind the posterior leaf of the broad ligament. +/- Ureteral dilatation.</p> <p>Involvement circumference (= or <math><360^\circ</math>) (dashed circle). Length of involved ureter. Distance from ureterovesical junction</p> 	
<p>Uterine artery</p>	<p>Fibrotic infiltration surrounding the uterine artery (serpiginous flow void) (arrows) with abolition of the peri-artery cellular and fat signal</p> 	
<p>Pelvic wall, external iliac and/or obturator vessels</p>	<p>Fibrotic infiltration of external iliac and obturator vessels (dashed circles) and obturator muscles, up to the pelvic wall/obturator muscle.</p> 	

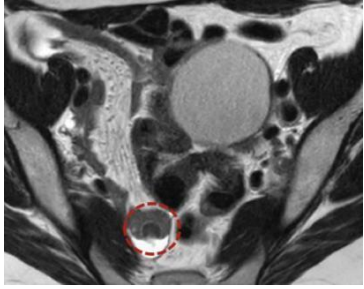
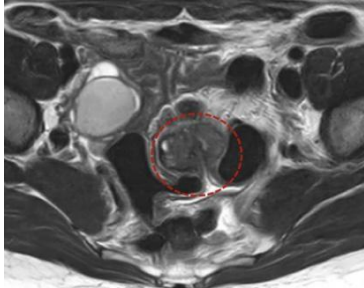
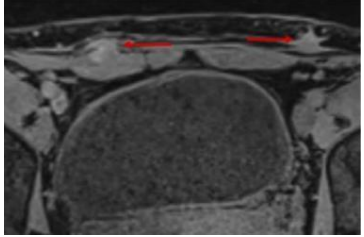
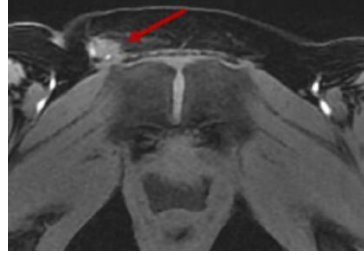
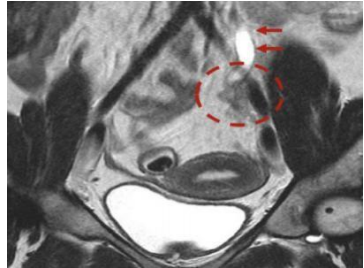
POSTEROCENTRAL COMPARTMENT

Anatomic Structure	Findings and Reporting
<p>Rectum and rectosigmoid junction</p>	<p>Thickening or mass of the rectosigmoid wall.</p> <p>Distance to the anal verge and the lower point of the lesion (white dashed line).</p> <p>Location within the rectosigmoid, considering the distance between the anal verge and the middle point of the rectal lesion, as follows:</p> <ul style="list-style-type: none"> • Lower rectum (0–5 cm). • Middle rectum (5–10 cm). • Upper rectum (10–15 cm). • Recto-sigmoid junction (>15 cm). <p>O'clock position.</p> <p>The length (red dashed line), transverse axis and the thickness (double-headed arrows).</p> <p>Circumference (by degree or by dividing the rectal wall into eight radii).</p> <p>Submucosal edema.</p>
	
	<p>Features of solid rectosigmoid endometriosis include a “mushroom cap” sign, which is considered a specific finding of solid invasive endometriosis of the rectosigmoid colon on T2-weighted MR images.</p> <p>The low-signal-intensity base of the mushroom is the endometriotic lesion (red asterisk), whereas the high-signal-intensity cap represents the mucosa and submucosa (yellow arrows), which are displaced into the bowel lumen.</p> <p>Source: Case courtesy of Gustavo Aguiar, Radiopaedia.org, rID: 68037</p>
	

LEFT AND RIGHT POSTEROLATERAL COMPARTMENTS

Anatomic Structure	Findings and Reporting	
<p>Distal uterosacral ligaments "Distal" correspond to distal two thirds of USL >2 cm from torus</p>	<p><u>Positive diagnosis (dashed circle) if any of the following:</u> With or without hemorrhagic implant(s):</p> <ul style="list-style-type: none"> • Regular or irregular fibrotic thickening >5 mm • Nodular (defined as if nodule is present in two planes) • Retraction (spiculate defined as irregularity present in two planes, distortion of the shape, surrounding fat infiltration) <p>Presence of hemorrhagic implant(s), whatever the thickening</p> <p><u>Uncertain diagnosis when:</u> Irregular or pseudonodular (defined as present in only one plane) AND Fibrotic thickening between 3 and 5 mm.</p>	
<p>Sacro-recto-genital septum</p>	<p>Fibrotic nodular infiltration, either unilateral or bilateral, with the loss of the normal aspect of the subperitoneal pararectal cellular sheet, under the uterosacral ligament, with thickening of the fascia recti (arrow).</p> <p>Height (double-headed arrows) and distance or extension to the iliococcygeus muscle of levator ani (dashed arrows).</p>	
<p>Sacral roots, sciatic nerve, internal iliac vessels and pelvic wall</p>	<p>Fibrotic infiltration of sacral roots (dashed arrows), sciatic nerve, internal iliac vessels, and pelvic wall (arrow), often in continuity with the infiltration of the sacro-recto-genital septum.</p>	

EXTRA-PELVIC LOCATIONS

Anatomic Structure	Findings and Reporting	
Cecum-ileum-appendix	<p>Report each lesion independently.</p> <p>Fibrotic nodular infiltration of the caecum and ileum (dashed circle) (+/- ileum distension) including distance to the ileocecal valve or appendicular wall (+/- appendix distension), with size of lesion.</p>	
Sigmoid colon	<p>Lesion located above the rectosigmoid junction, indicating the proximal or distal part (dashed circle) of the sigmoid.</p> <p>Size and number of lesions.</p> <p>Length, thickness and circumference +/- upstream distension.</p>	
Abdominal wall	<p>Fibrotic nodular infiltration +/- hemorrhagic cystic area of the rectus muscles and/or lateral muscles, or subcutaneous fat tissue with size, percentage of muscular Infiltration, relationship with the muscle fasciae and distance to the skin.</p> <p>Umbilical nodule.</p>	
Inguinal regions	<p>Nodular fibrotic infiltration +/- hemorrhagic cystic area of the terminal extra pelvic part of the round ligament at the level of the superficial orifice of inguinal canal (arrows) or in the labia majora.</p>	
Ureters at the level of common iliac artery	<p>Fibrotic infiltration with disappearance of the peri ureteric fat signal (dashed circle). +/- ureteral dilatation (arrows).</p>	

APPENDIX 5: Sample Counselling Checklist

<p style="text-align: center;"><u>COUNSELLING CHECKLIST FOR</u> <u>PEOPLE LIVING WITH ENDOMETRIOSIS</u></p> <p>1. Diagnosis and Disease Understanding</p> <ul style="list-style-type: none"> <input type="checkbox"/> Explain what endometriosis is and common symptom patterns <input type="checkbox"/> Discuss uncertainty between symptom severity and disease stage <input type="checkbox"/> Clarify limits of imaging (superficial peritoneal disease may not be detected) <input type="checkbox"/> Discuss possibility of co-existing deep or ovarian disease <input type="checkbox"/> Review differential diagnoses if relevant <p>2. Symptom Assessment</p> <ul style="list-style-type: none"> <input type="checkbox"/> Dysmenorrhoea <input type="checkbox"/> Chronic pelvic pain <input type="checkbox"/> Dyspareunia <input type="checkbox"/> Dyschezia / bowel symptoms <input type="checkbox"/> Urinary symptoms <input type="checkbox"/> Fatigue and impact on daily life <input type="checkbox"/> Mental health impact <input type="checkbox"/> Other (specify): _____ <p>3. Fertility Considerations</p> <ul style="list-style-type: none"> <input type="checkbox"/> Current pregnancy intentions <input type="checkbox"/> Effect of endometriosis on fertility <input type="checkbox"/> Impact of surgery on ovarian reserve <input type="checkbox"/> Risk of reduced ovarian reserve after repeat or bilateral surgery <input type="checkbox"/> Referral for fertility assessment if appropriate <p>4. Medical Management</p> <ul style="list-style-type: none"> <input type="checkbox"/> Expected benefits for pain control <input type="checkbox"/> Time to symptom improvement <input type="checkbox"/> Side effects (short- and long-term) <input type="checkbox"/> Duration of treatment <input type="checkbox"/> Impact on fertility (contraceptive effect) <input type="checkbox"/> When to review or change therapy 	<p>5. Surgical Management</p> <ul style="list-style-type: none"> <input type="checkbox"/> Indications for surgery <input type="checkbox"/> Expected pain relief <input type="checkbox"/> Risk of recurrence <input type="checkbox"/> Risk of complications (bowel, bladder, ureter, ovarian damage) <input type="checkbox"/> Impact on ovarian reserve <input type="checkbox"/> Possibility of incomplete excision <input type="checkbox"/> Recovery time <p>6. Ovarian Endometrioma (if present)</p> <ul style="list-style-type: none"> <input type="checkbox"/> Cystectomy vs drainage/ablation <input type="checkbox"/> Recurrence risk <input type="checkbox"/> Effect on ovarian reserve <input type="checkbox"/> Risk of ovarian failure (rare but possible) <p>7. Multidisciplinary and Supportive Care</p> <ul style="list-style-type: none"> <input type="checkbox"/> Pelvic physiotherapy <input type="checkbox"/> Pain management services <input type="checkbox"/> Psychological support <input type="checkbox"/> Sexual health support <input type="checkbox"/> Diet and lifestyle advice <p>8. Shared Decision-Making</p> <ul style="list-style-type: none"> <input type="checkbox"/> Discuss patient priorities (pain relief, fertility, avoidance of surgery, etc.) <input type="checkbox"/> Balance benefits and risks of each option <input type="checkbox"/> Consider cost and availability <input type="checkbox"/> Agree on a clear management plan <input type="checkbox"/> Arrange follow-up
---	--

16.0 References

Adamson GD, Pasta DJ. Endometriosis fertility index: the new, validated endometriosis staging system. *Fertil Steril*. 2010;94(5):1609–1615.

Alexander, A., & Nougaret, S. (2026). Reference handbook of gynecologic pelvic MRI. *Radiographics*, 46(2), e250029.

American College of Obstetricians and Gynecologists. Practice Bulletin No. 114: Management of Endometriosis. *Obstet Gynecol*. 2010;116(1):223–236.

American College of Obstetricians and Gynecologists. Dysmenorrhea and endometriosis in the adolescent. ACOG Committee Opinion No. 760. *Obstet Gynecol*. 2018;132:e249–258.

American College of Obstetricians and Gynecologists. Clinical Practice Guideline: Diagnosis of Endometriosis. 2026.

Australian living evidence guideline: endometriosis – 2025. The Royal Australian and New Zealand College of Obstetricians and Gynecologists (RANZCOG). Available at: <https://reproduct-endo.com/article/view/341111>

Becker CM, Bokor A, Heikinheimo O, et al. ESHRE guideline: endometriosis. *Hum Reprod Open*. 2022;2022(2):hoac009.

Crump J, Suker A, White L. Endometriosis: A review of recent evidence and guidelines. *Aust J Gen Pract*. 2024;53(1–2):11–18.

Farquhar C. Endometriosis. *BMJ*. 2007;334(7587):249–253.

Guerriero, S., et al. (2016). Systematic approach to sonographic evaluation of the pelvis in women with suspected endometriosis, including terms, definitions and measurements: A consensus opinion from the International Deep Endometriosis Analysis (IDEA) group. *Ultrasound in Obstetrics & Gynecology*, 48(3), 318–332

Habana MA, Factor PA. Recurrent endometriosis: Contemporary challenges. *Philipp J Reprod Endocrinol Infertil*. 2020:39–49.

Harada T, Taniguchi F, Kitajima M, et al. Clinical practice guidelines for endometriosis in Japan (3rd ed.). *J Obstet Gynaecol Res*. 2022;48:2993–3044.

Imperiale L, Nisolle M, Noël JC, Fastrez M. Three types of endometriosis: Pathogenesis, diagnosis and treatment. State of the art. *J Clin Med*. 2023;12(3):994.

Keckstein J, Saridogan E, Mechsner S, et al. The #Enzian classification: A comprehensive non-invasive and surgical description system for endometriosis. *Acta Obstet Gynecol Scand*. 2021;100(7):1165–1175.

National Institute for Health and Care Excellence. Endometriosis: diagnosis and management (NICE Guideline No. 73, updated 2024). 2017. Available at: <https://www.nice.org.uk/guidance/ng73>

Panvino F, Paparella R, Pisani F, et al. Endometriosis in adolescence: A narrative review of the psychological and clinical implications. *Diagnostics*. 2025;15:548.

Revised American Society for Reproductive Medicine classification of endometriosis: 1996. *Fertil Steril*. 1997;67:817–821.

Rousset, P., et al. (2023). Deep pelvic infiltrating endometriosis: MRI consensus lexicon and compartment-based approach from the ENDOVALIRM group. *Diagnostic and Interventional Imaging*, 104(3), 95–112.

Steenberg CK, Tanbo TG, Qvigstad E. Endometriosis in adolescence: Predictive markers and management. *Acta Obstet Gynecol Scand*. 2013;92:491–495.